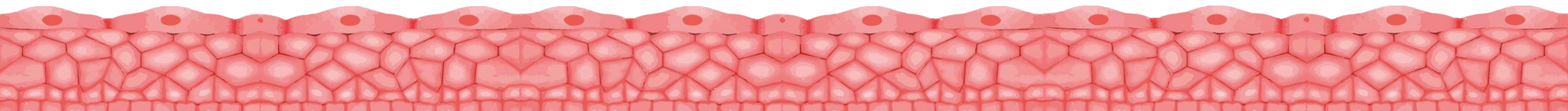
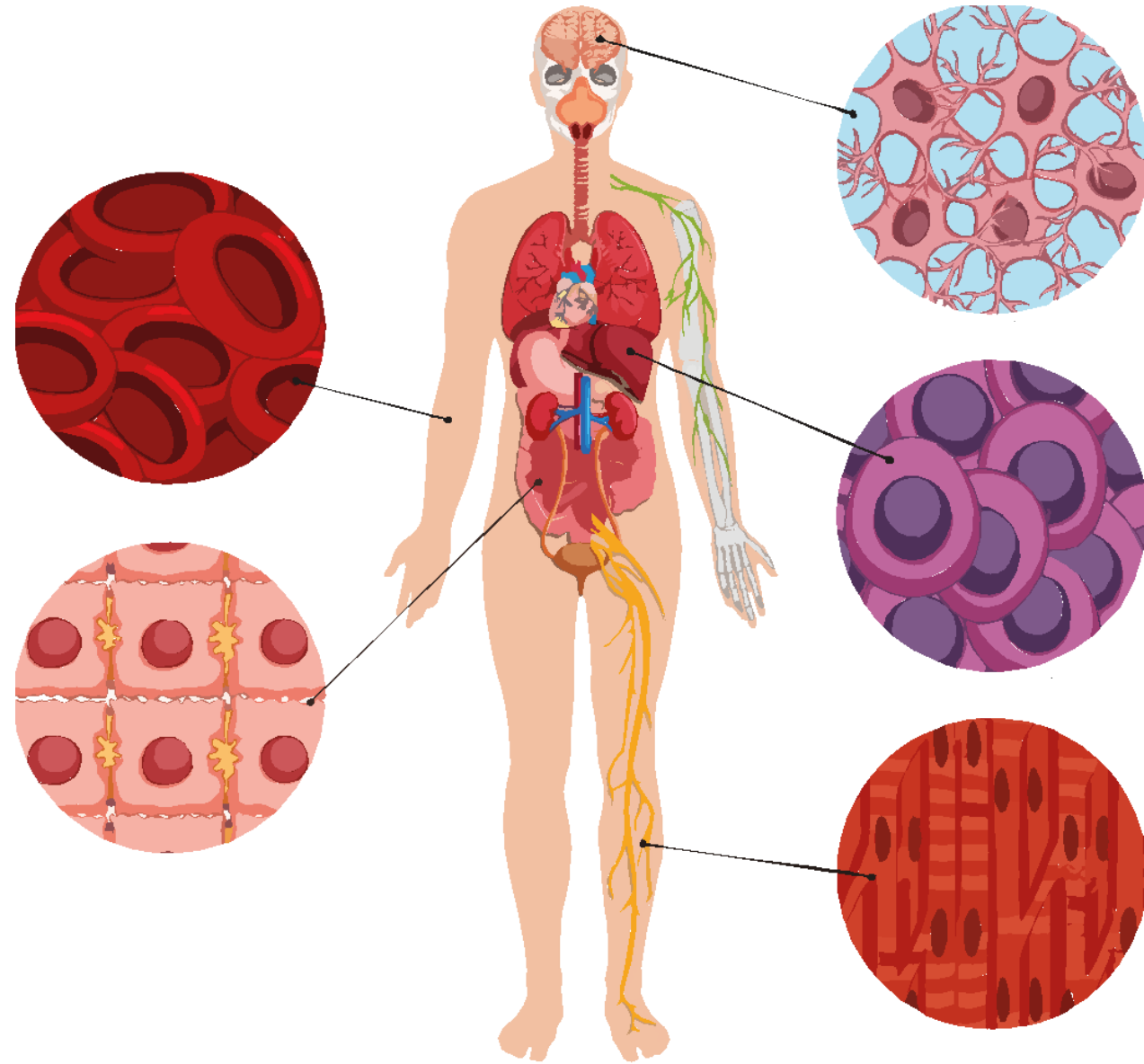


Citologija i tkiva

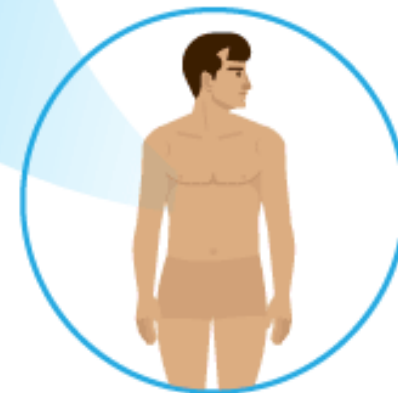
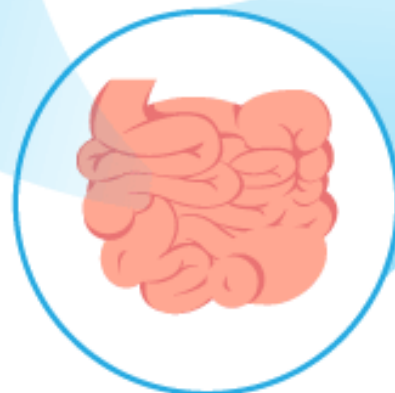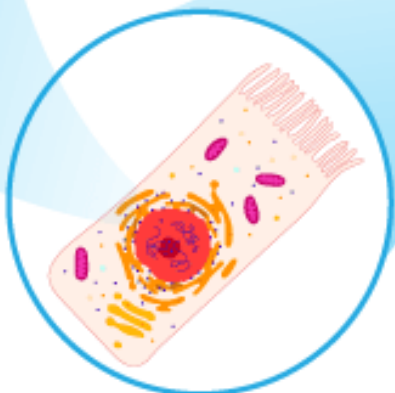
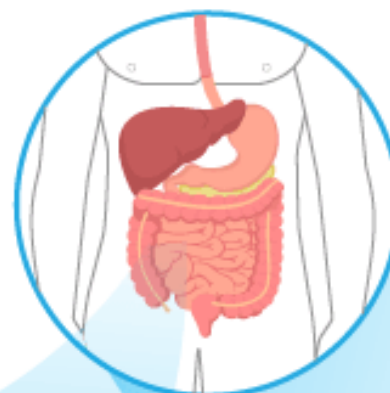
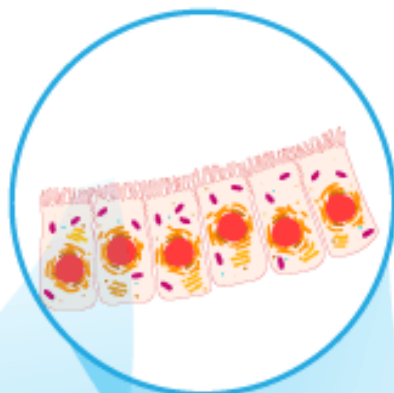Mijat BOŽOVIĆ



organela

tkivo

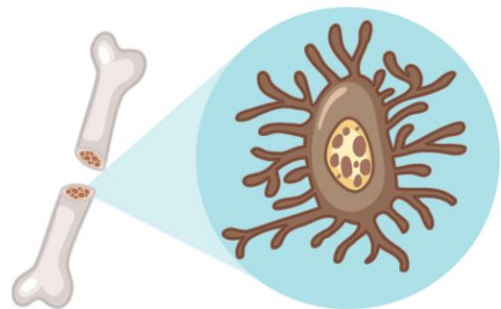
sistem organa



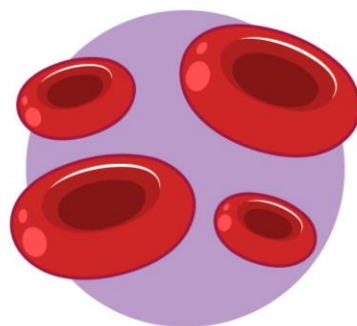
ćelija

organ


organizam



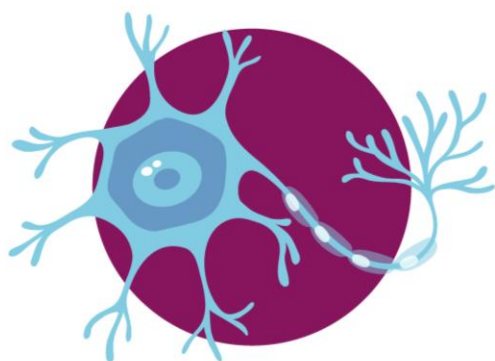
koštana ćelija



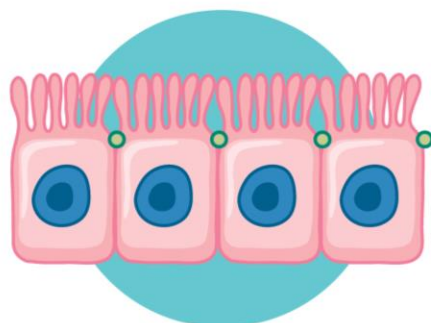
crvena krvna zrnca




bijele ćelije krvi



nervna ćelija



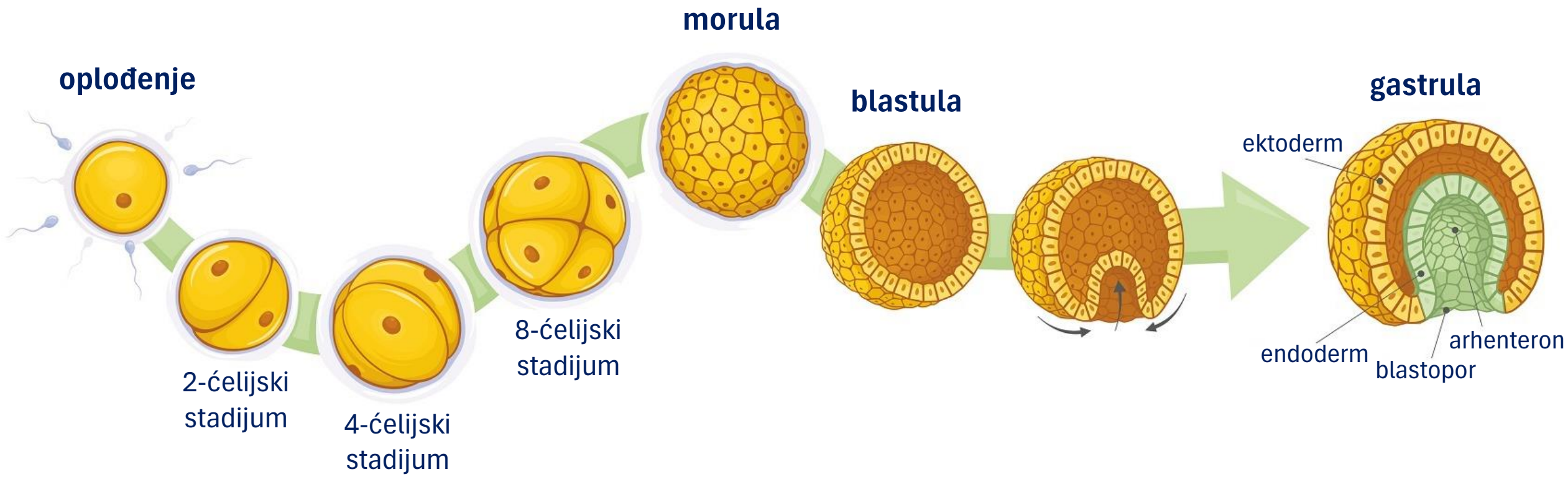
epitelne ćelije



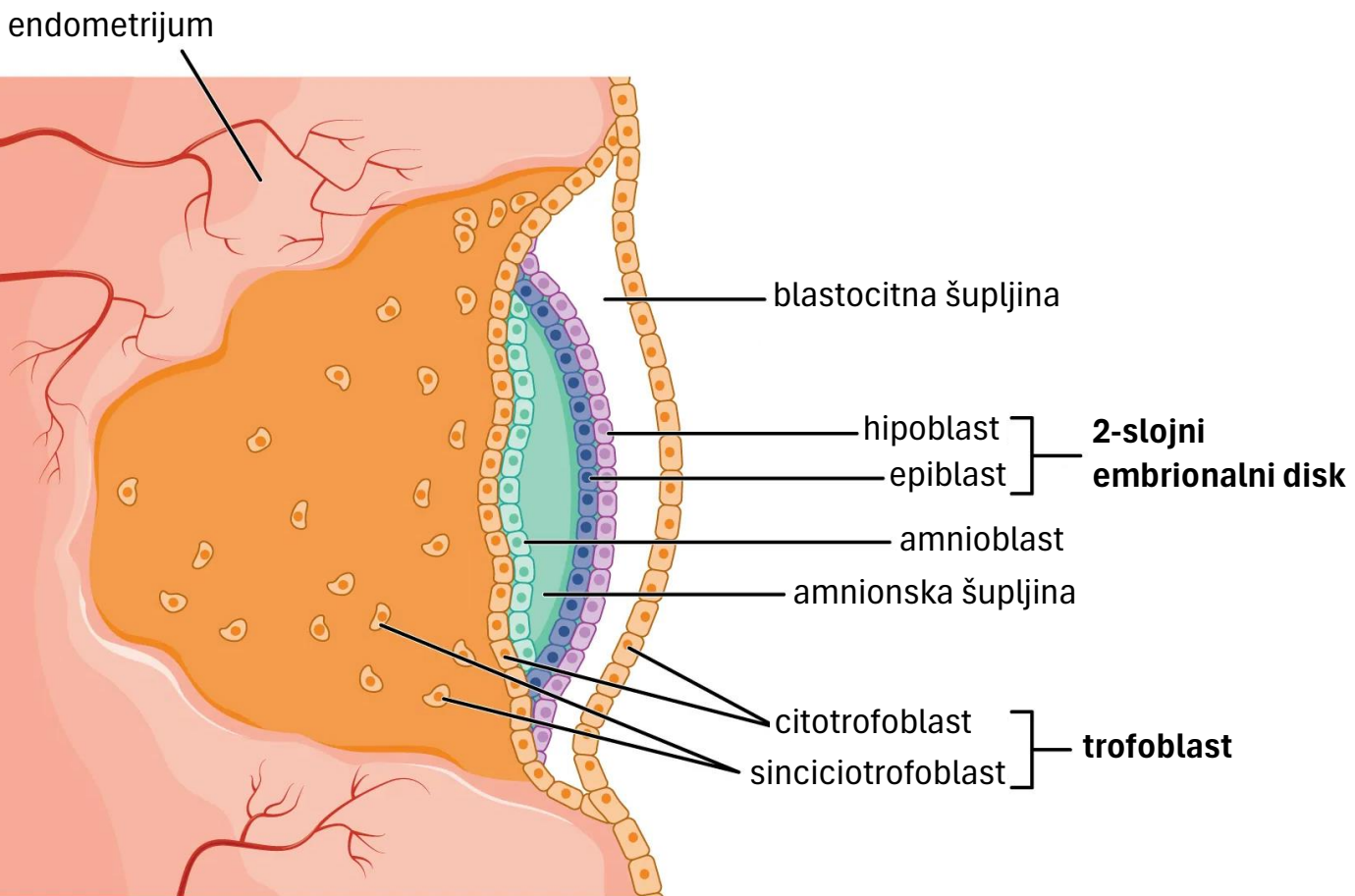
jajna ćelija



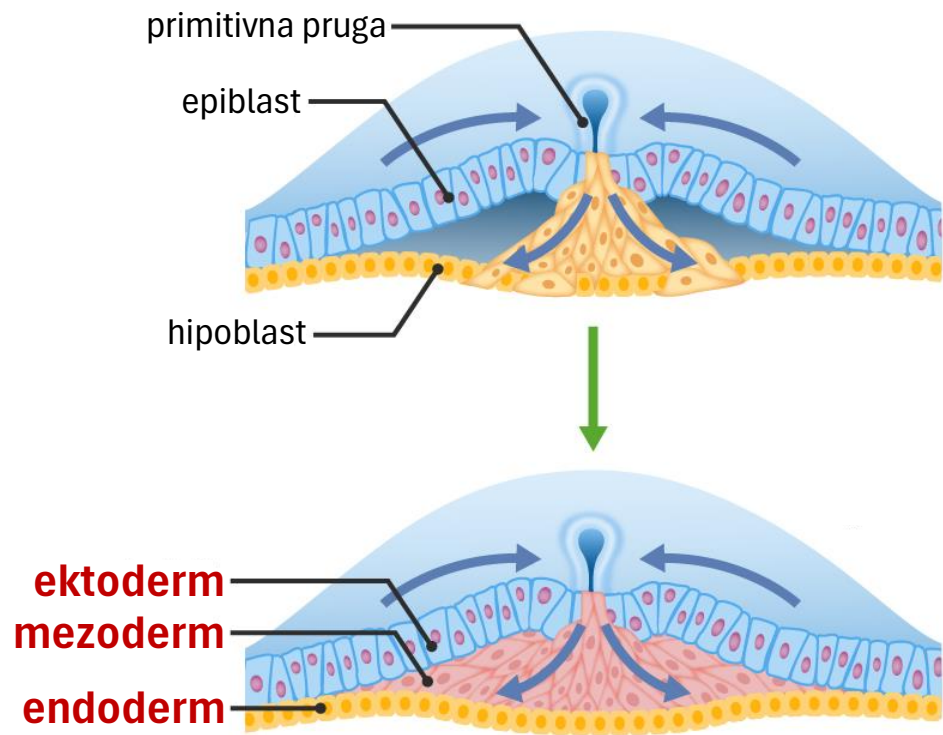
spermatozoid



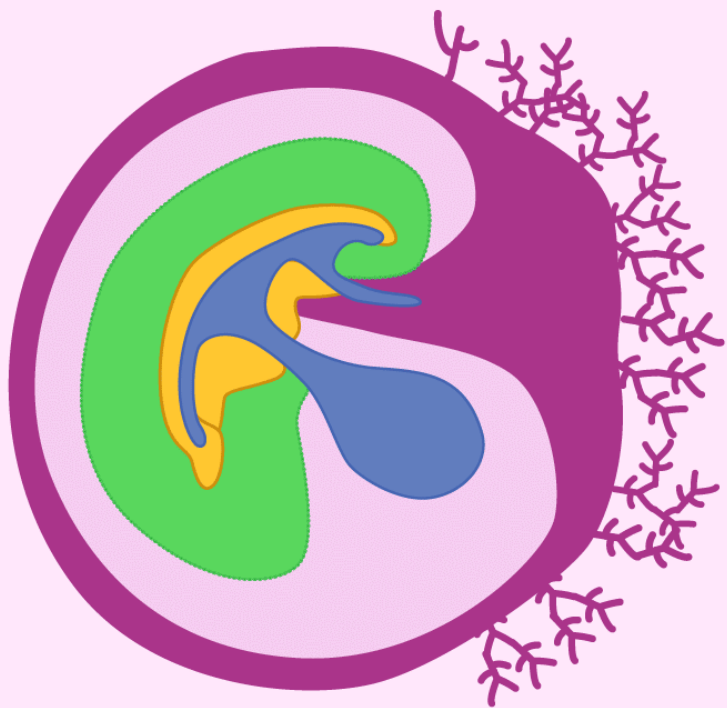OSVRT



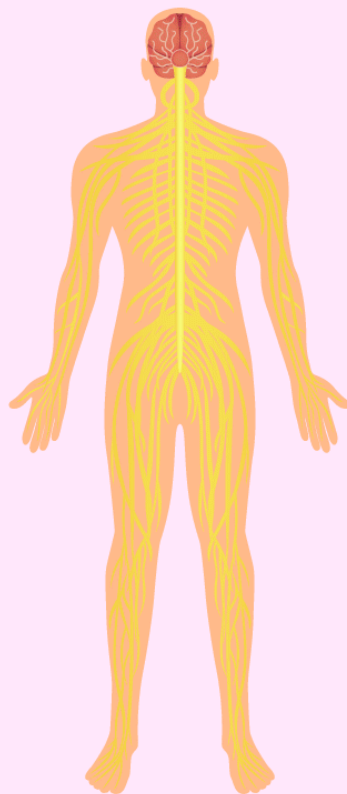

FORMIRANJE KLICINIHLISTOVA



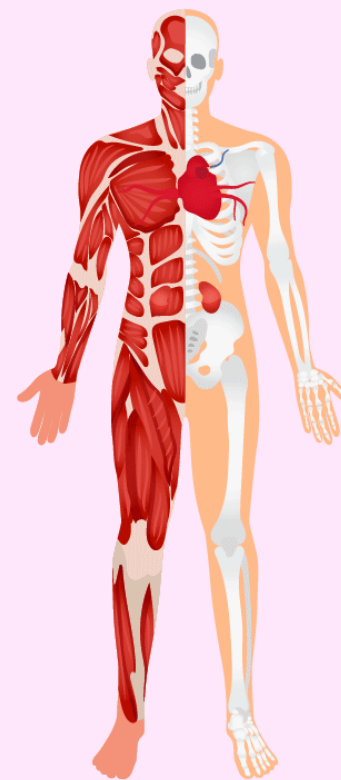OSVRT



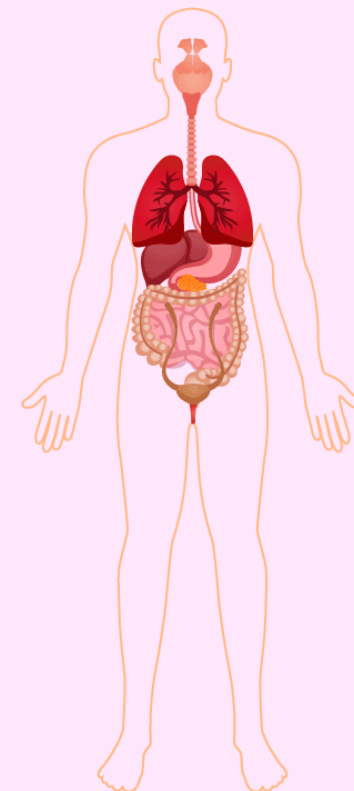
embrion koji započinje organogenezu



ektoderm



mezoderm



endoderm

DERIVATI KLICINIHLISTOVA


4

mišićno tkivo

srčano

skeletno

glatko



mišićna ćelija

šupljine unutrašnjih organa

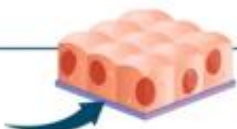

cilindrični



kockasti pločasti

koža



bazalna membrana

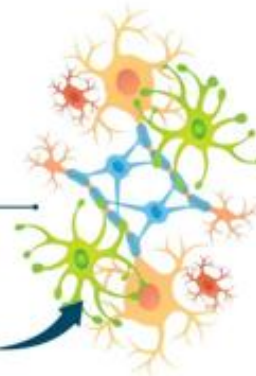
1

epitelno tkivo

mozak

kičmena moždina

nervi



nervna ćelija

3

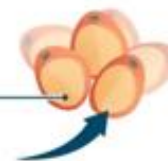
nervno tkivo

tetive

kosti



masno tkiva



adipocit

2

vezivno tkivo

2

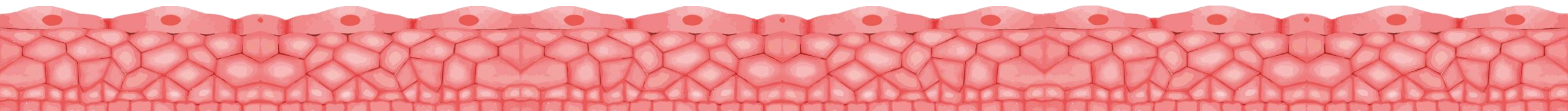
VEZIVNO TKIVO

Textus connectivus



Citologija i tkiva

Mijat BOŽOVIĆ



Komponente vezivnog tkiva
ćelije i ekstracelularni matriks

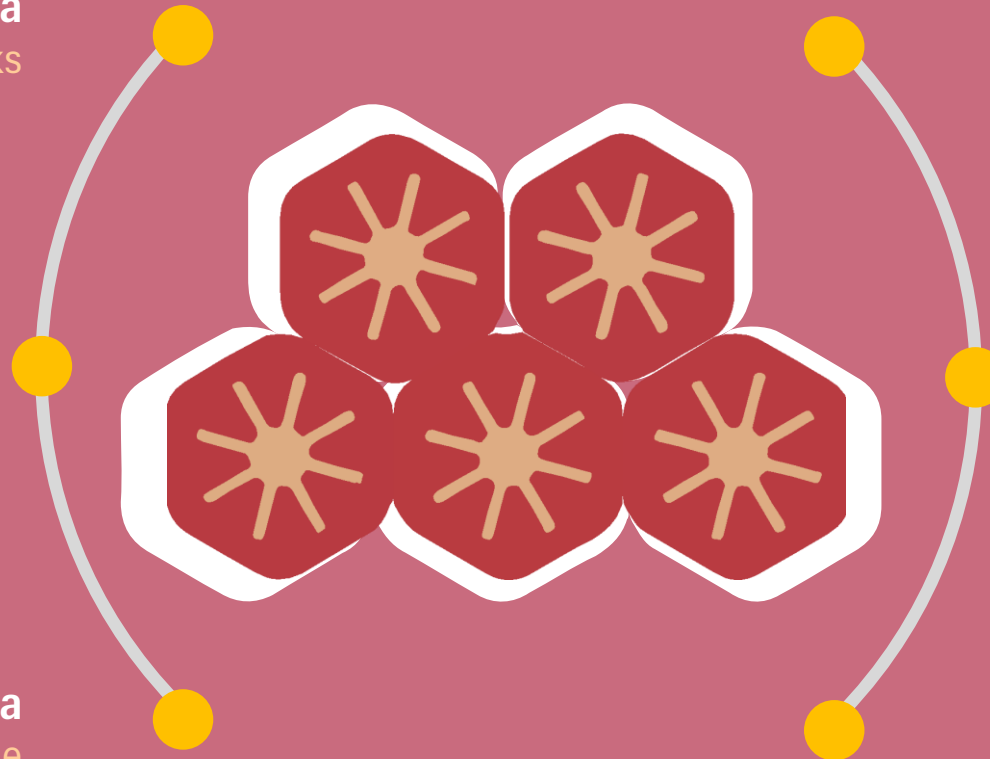
Ekstracelularni matriks
vlakna, osnovna supstanca i tkivna tečnost

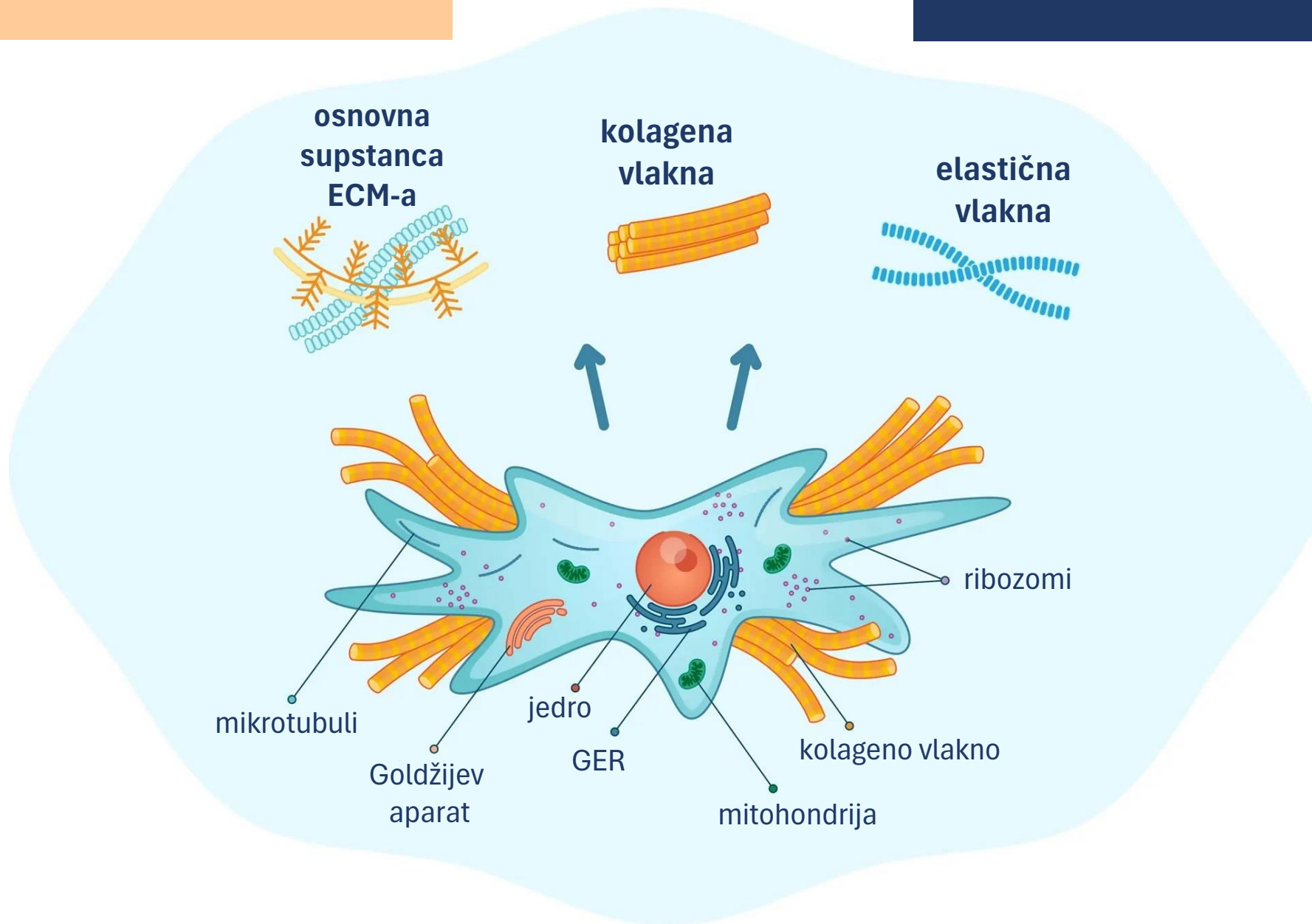
Porijeklo ćelija vezivnog tkiva
mezoderm

Vlakna vezivnog tkiva
kolagena, retikularna i elastična


Ćelije vezivnog tkiva
fiksne (stalne) i lutajuće

Osnovna supstanca
glikozaminoglikani, proteoglikani i glikoproteini






Kolagena vlakna




kolagen tip I
(najčešće)

Elastična vlakna



elastin

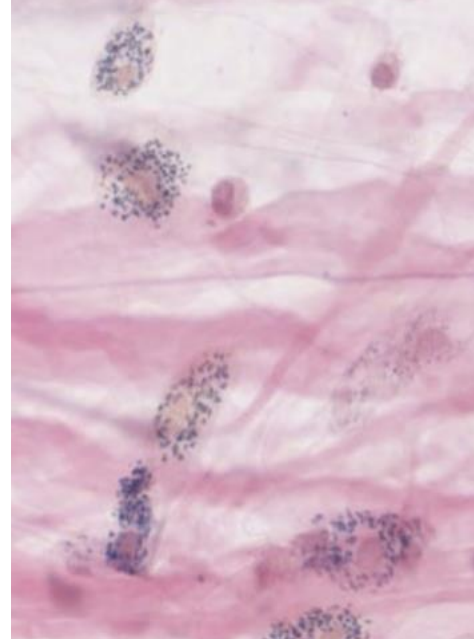
Retikularna vlakna



kolagen tip III

I)

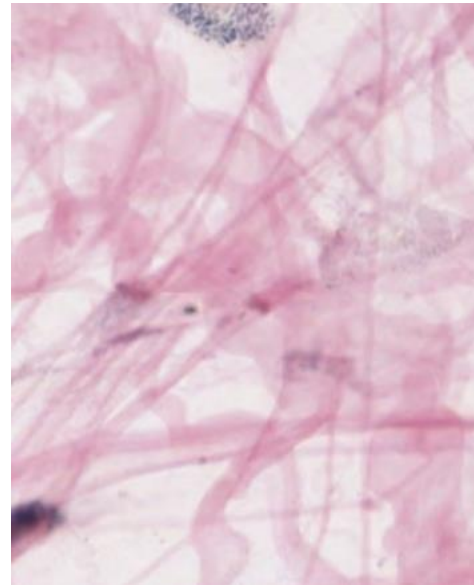
EMBRIONALNA



Mezenhimsko

Sluzno

Klasifikacija



II)

ADULTNA (ZRELA)

A) sa opštim svojstvima

Rastresito

Gusto

B) specijalizovana

1. Retikularno

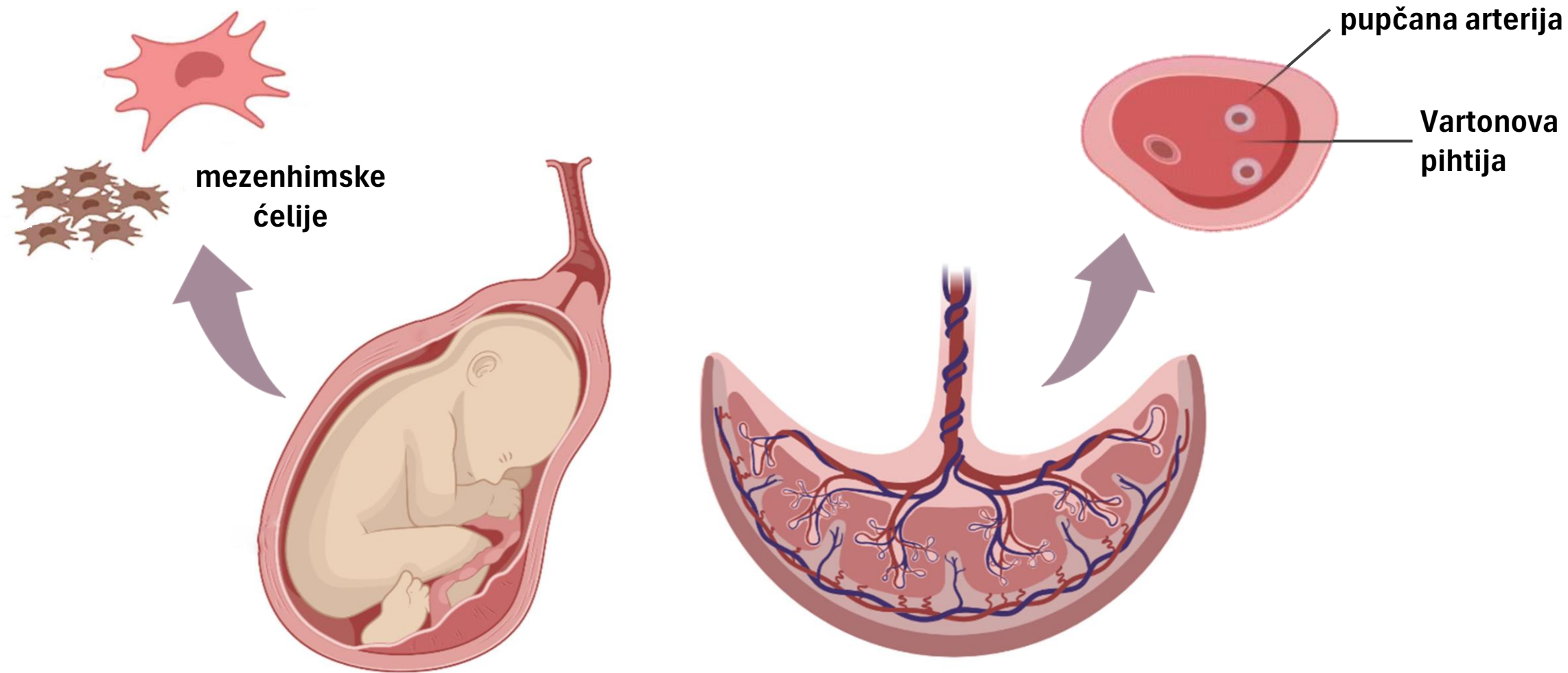
2. Masno

3. Hrskavičavo

4. Koštano

5. Krv

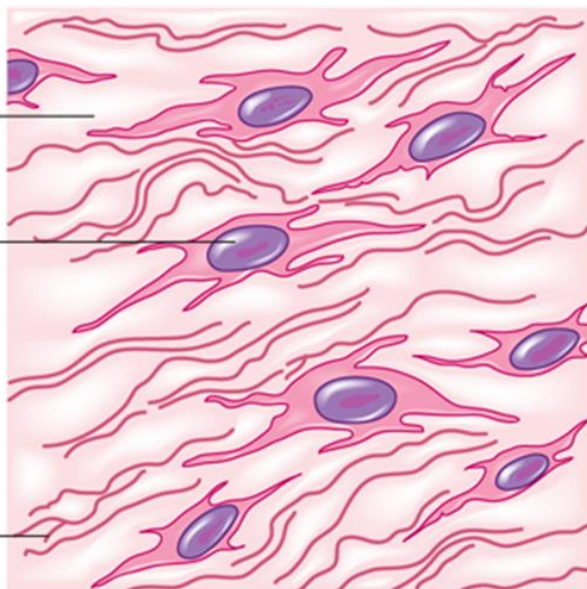
I) Embrionalna vezivna tkiva



1 mezenhimski
ćelija

2 ECM

3 retikularna
vlakna

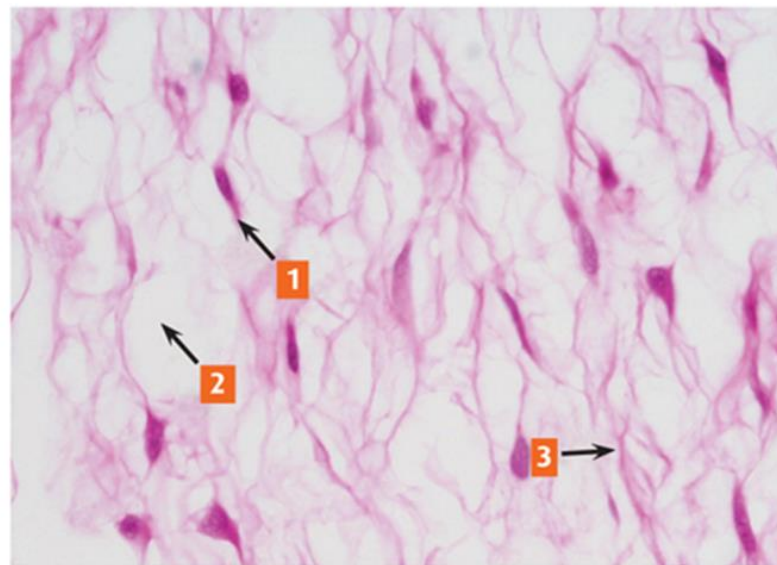
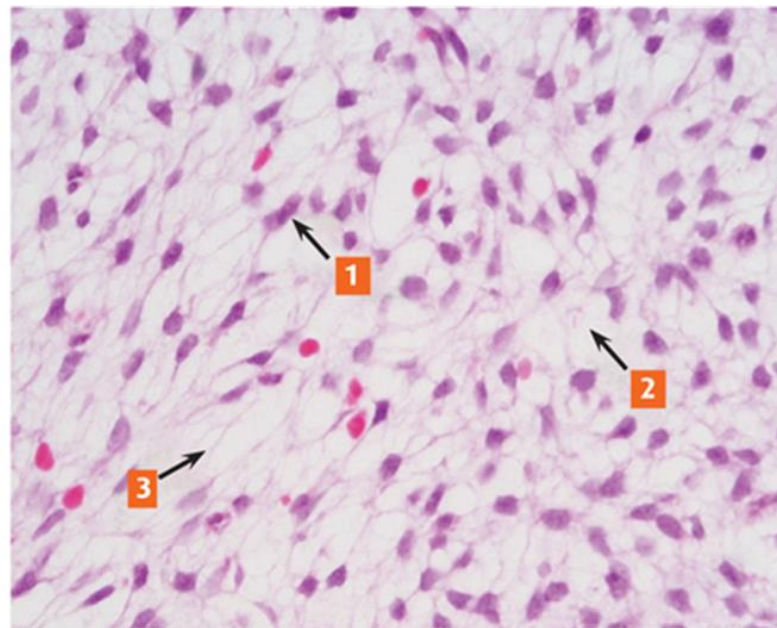
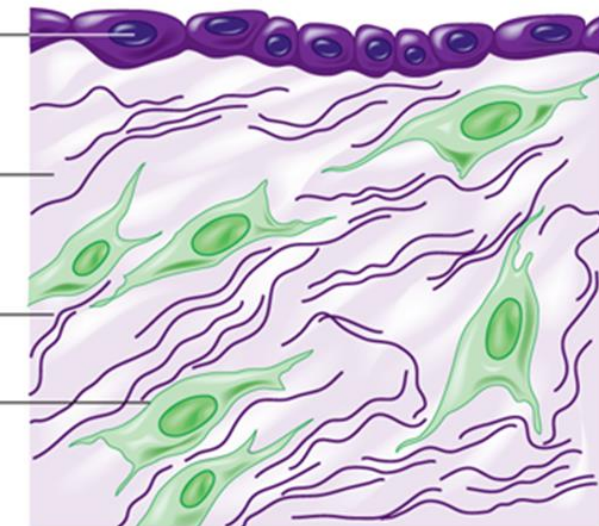


epitel
pupčane vrpce

2 ECM

3 kolagena
vlakna

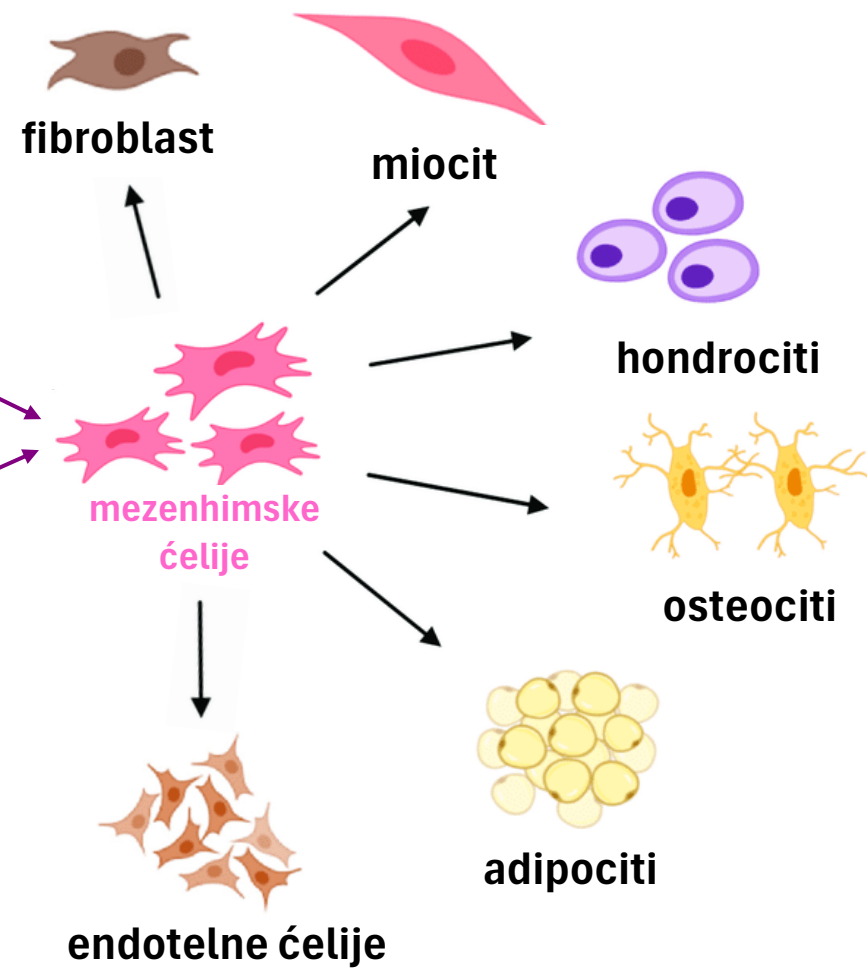
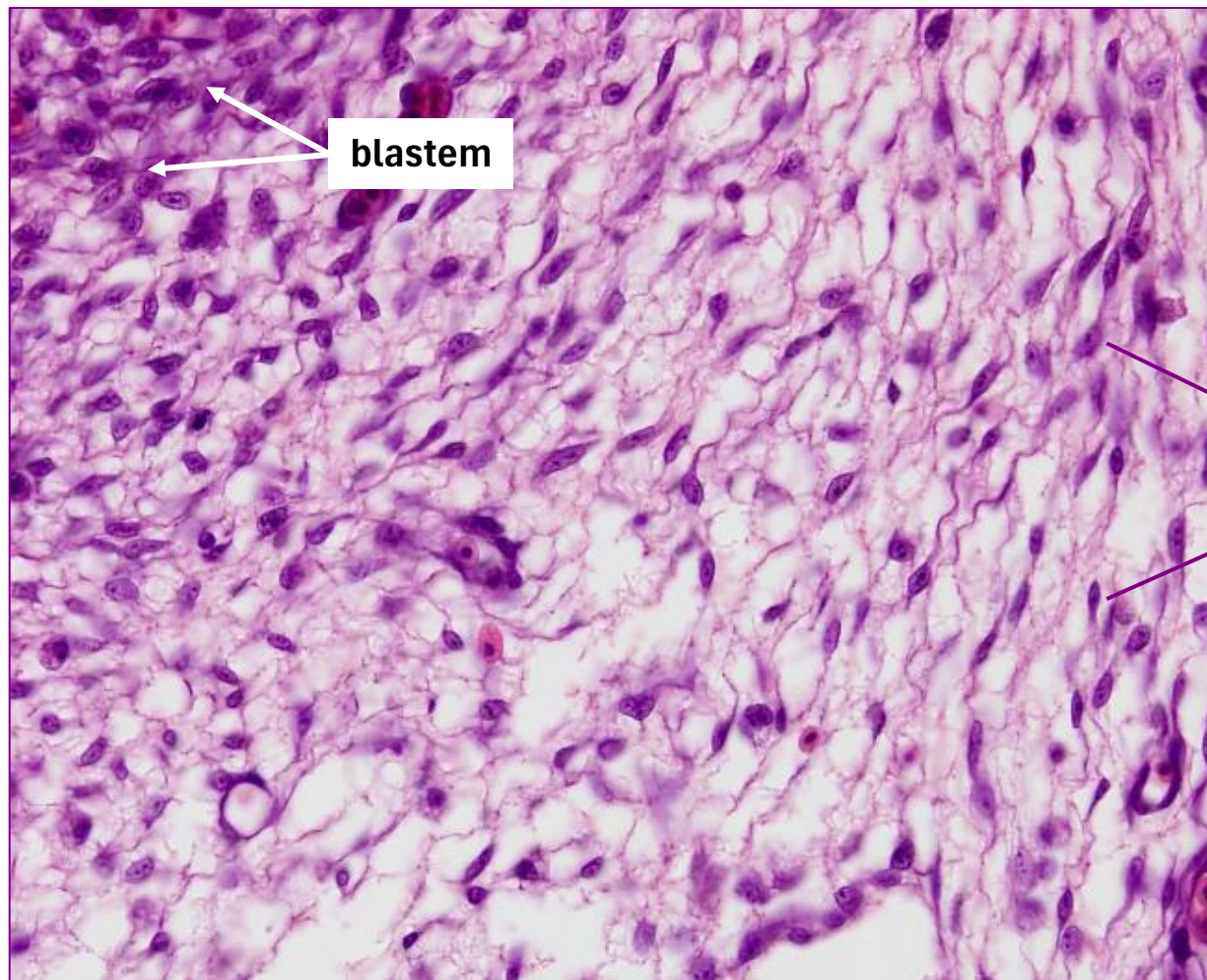
1 fibroblasti



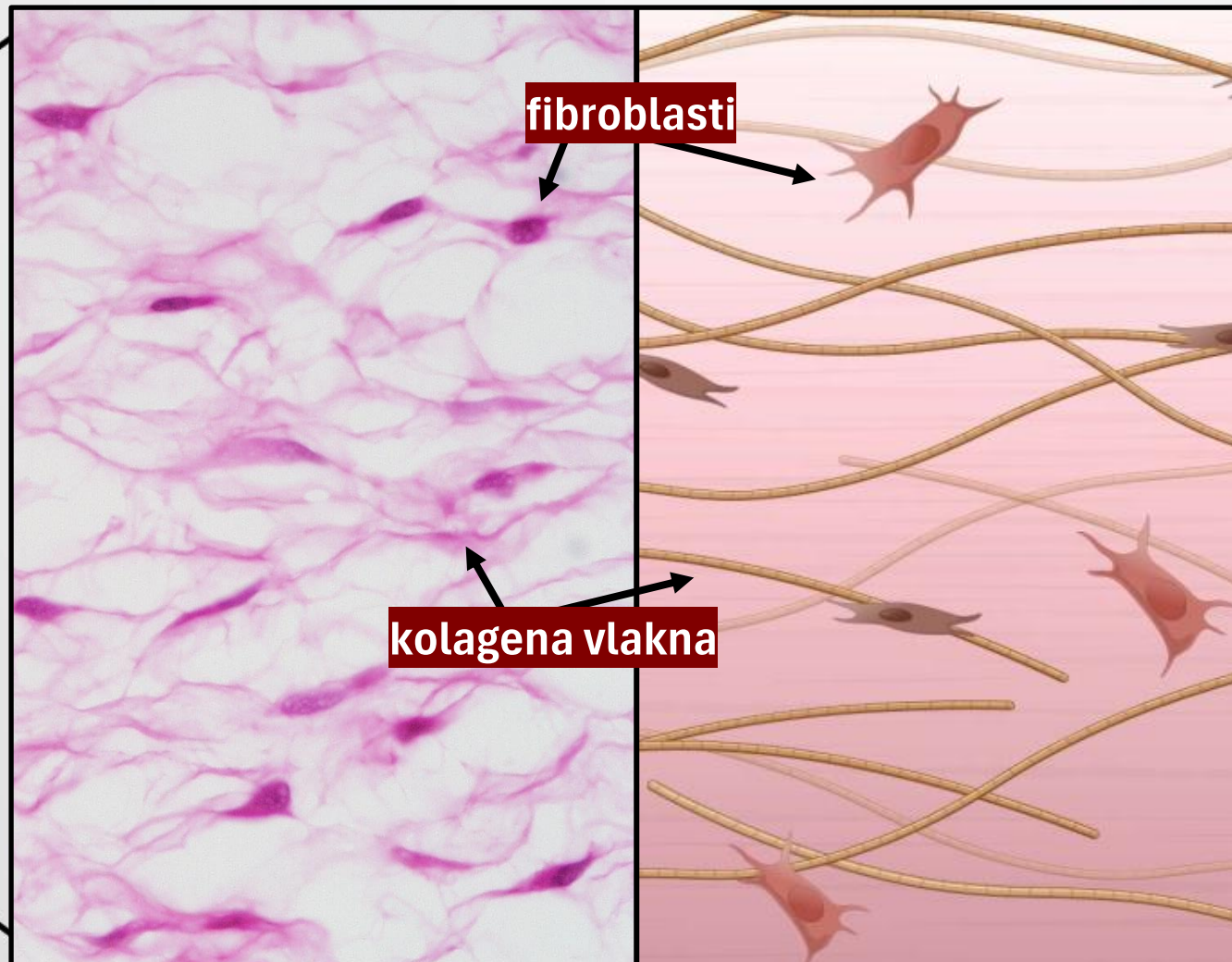
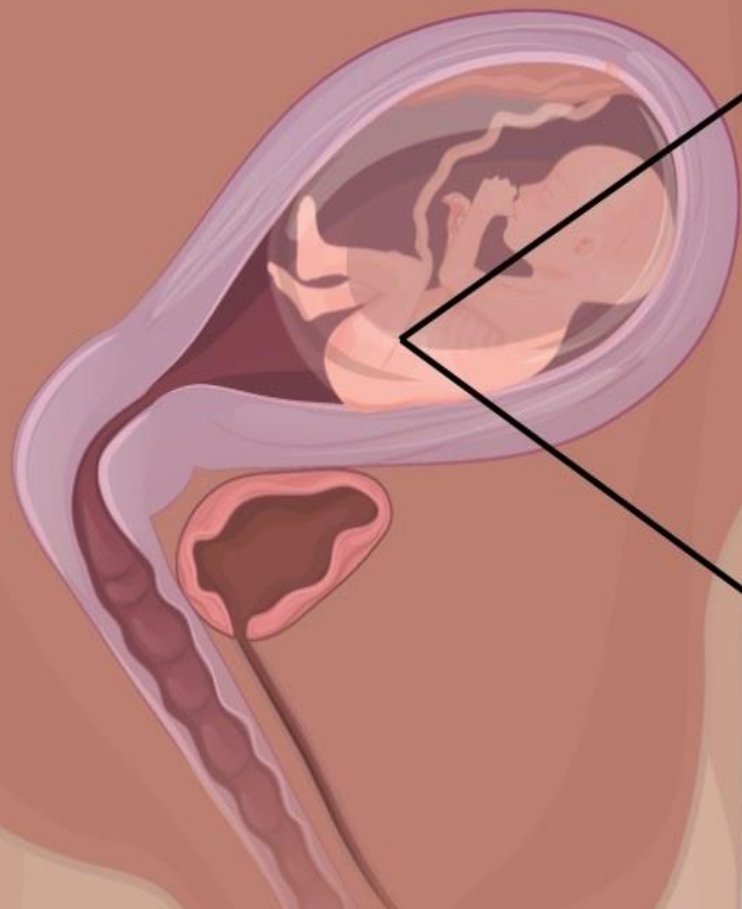mezenhimsko
vezivno tkivo

sluzno
vezivno tkivo

Mezenhimsko vezivno tkivo

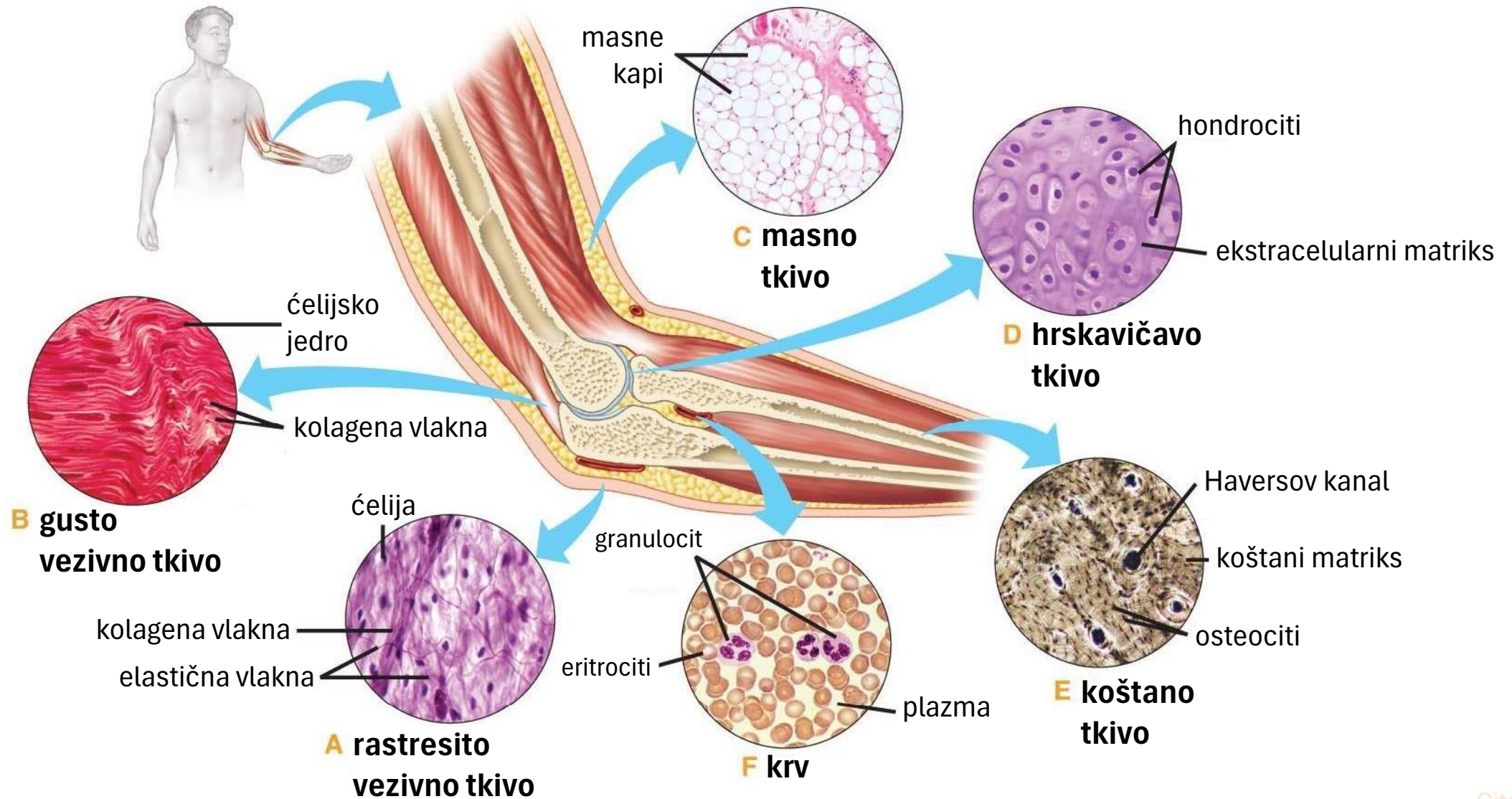


Sluzno vezivno tkivo

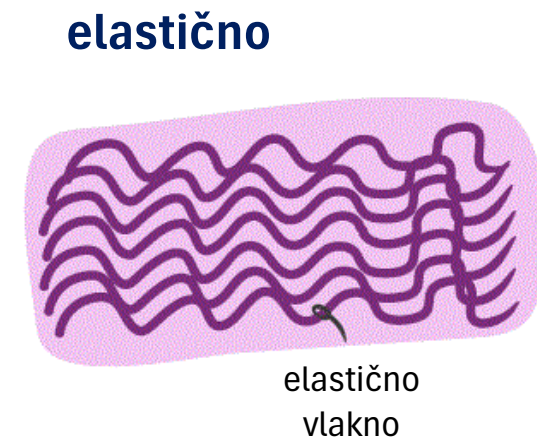
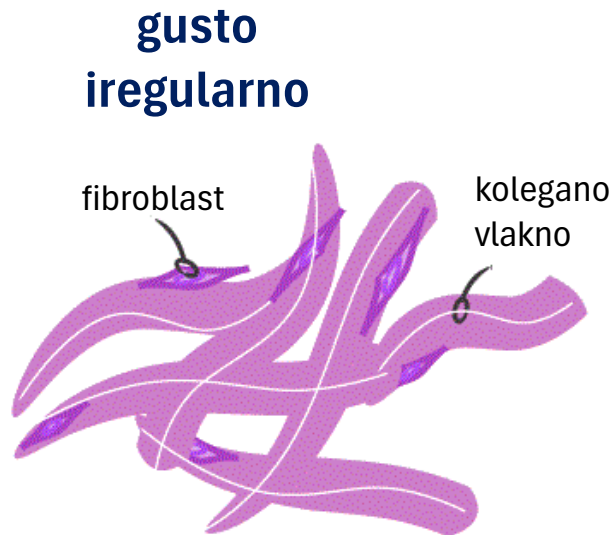
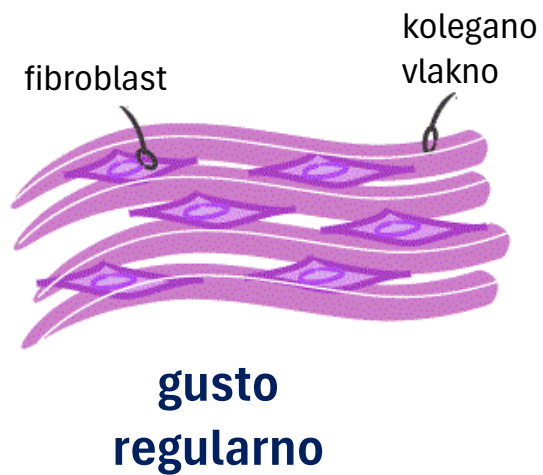
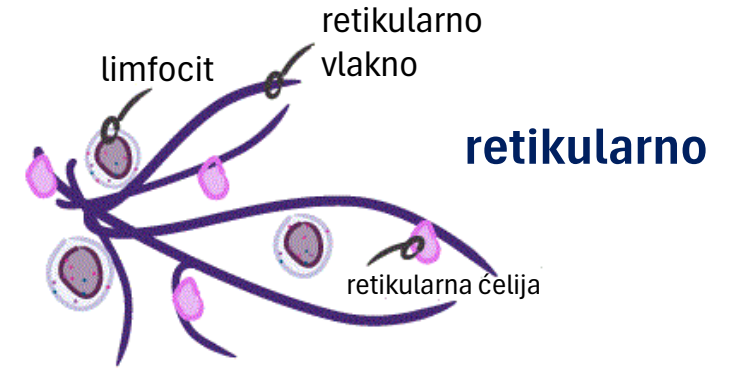
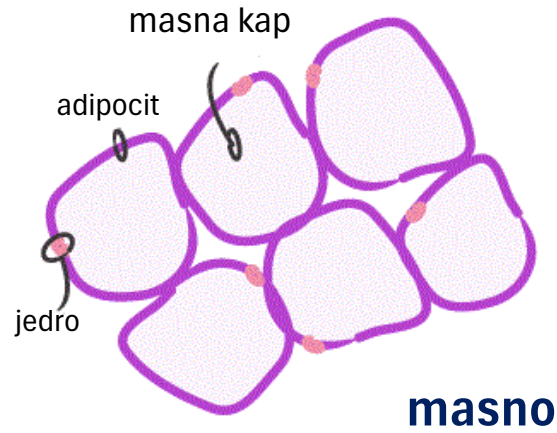
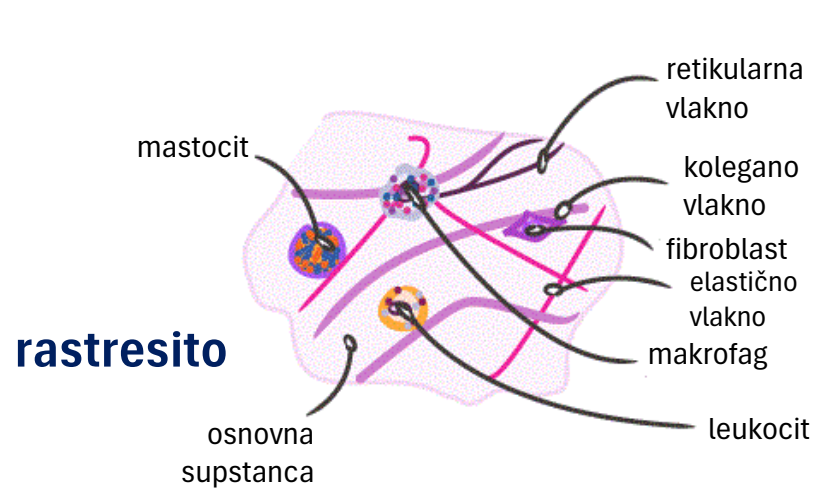


II)

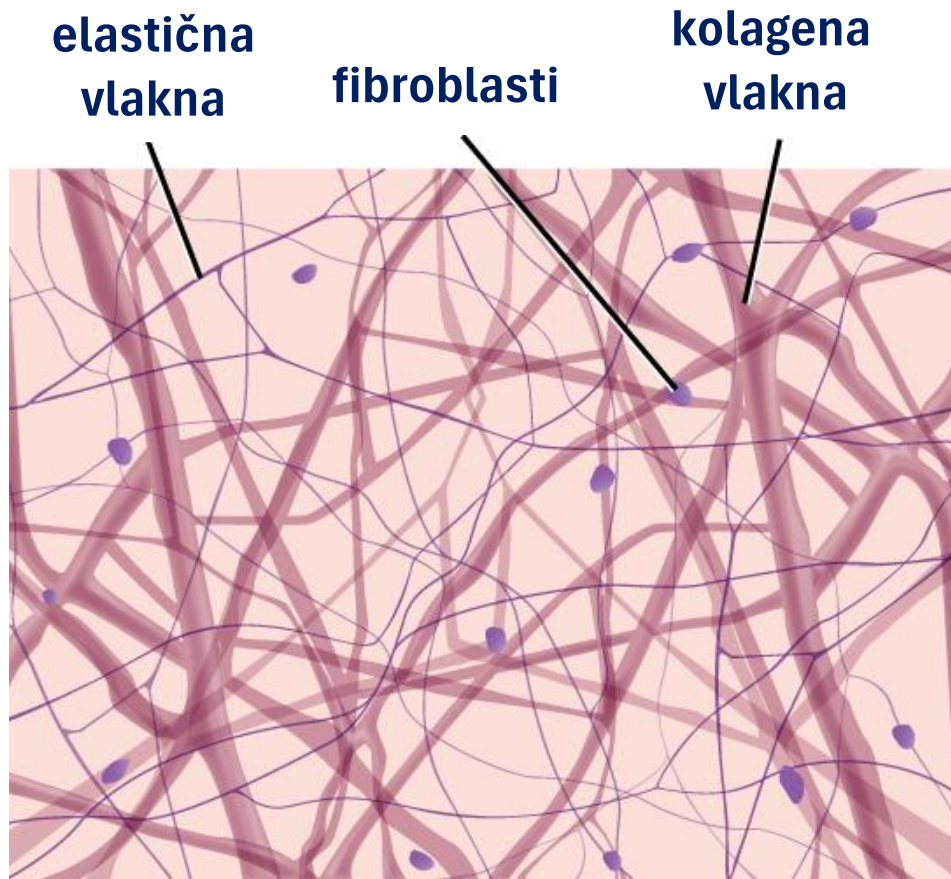
Adultna vezivna tkiva



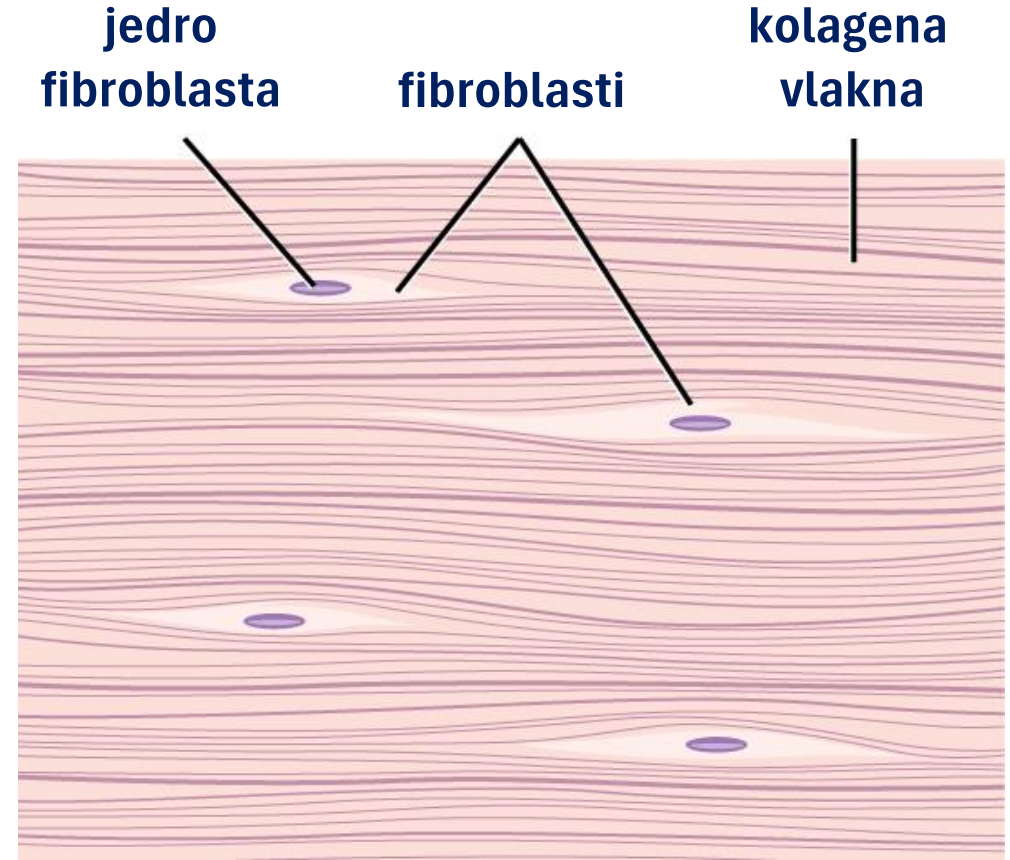
Organizacija vlakana i ćelija



A) Vezivna tkiva sa opštım svojstvima

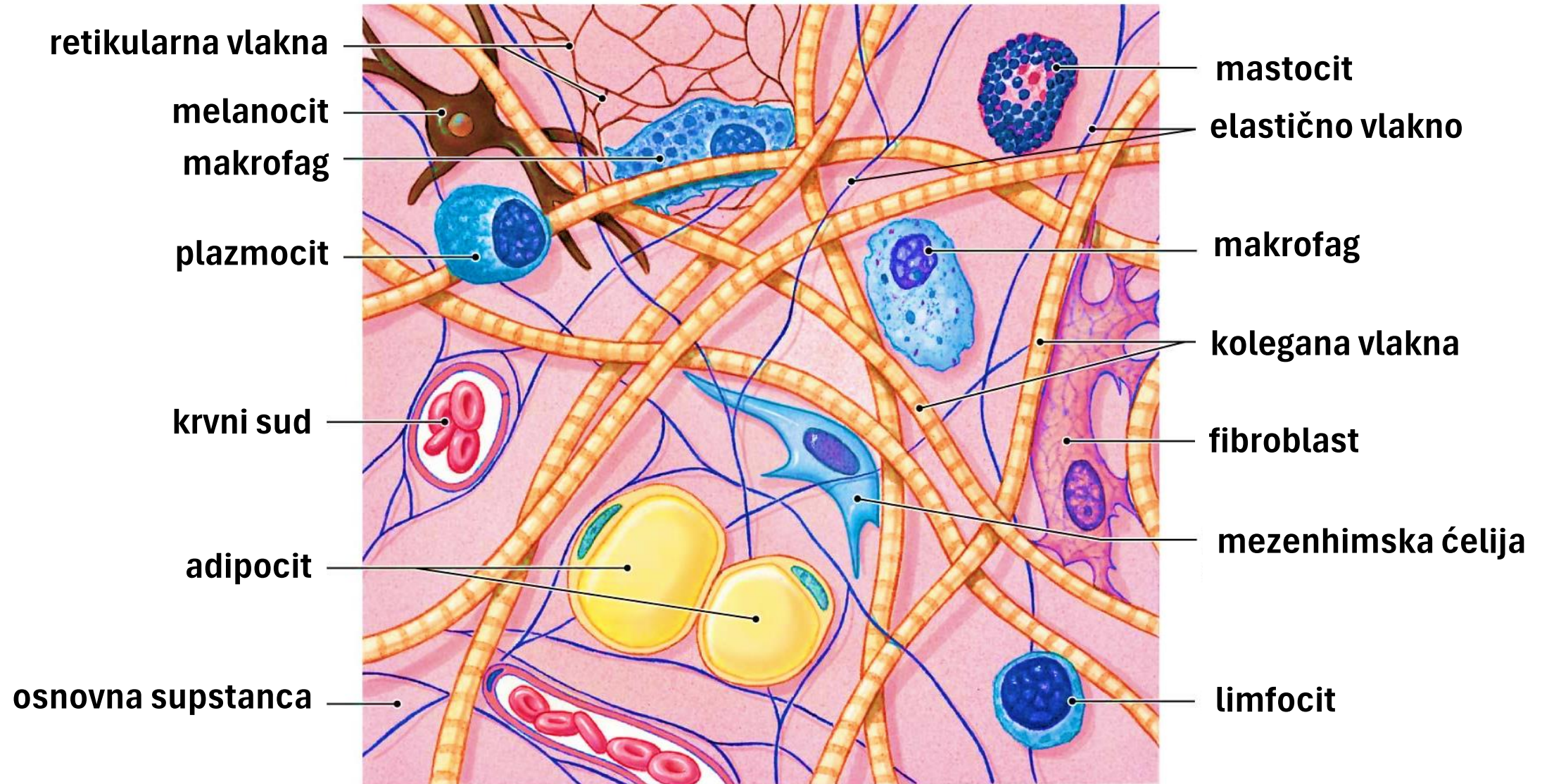


rastresito

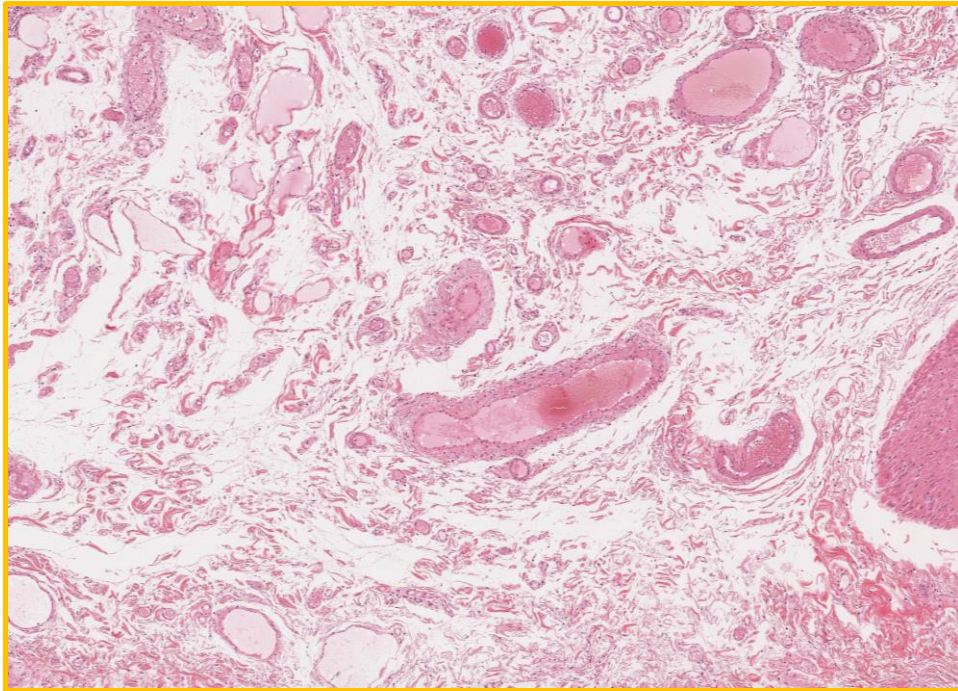


gusto

Ćelije i vlakna vezivnih tkiva sa opštim svojstvima



Textus connectivus laxus



veoma zastupljeno
u organizmu

pigmentno tkivo
kao specijalizovana forma

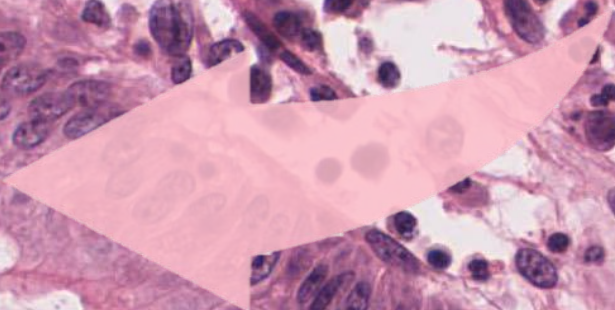
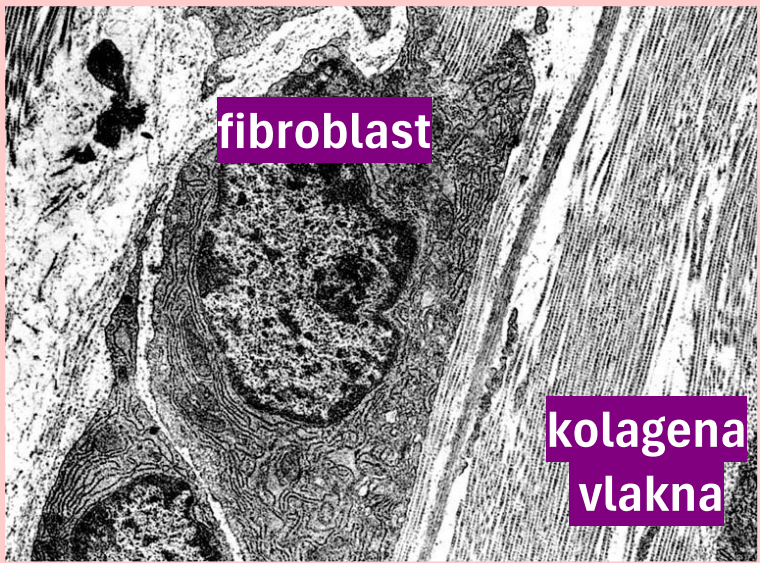
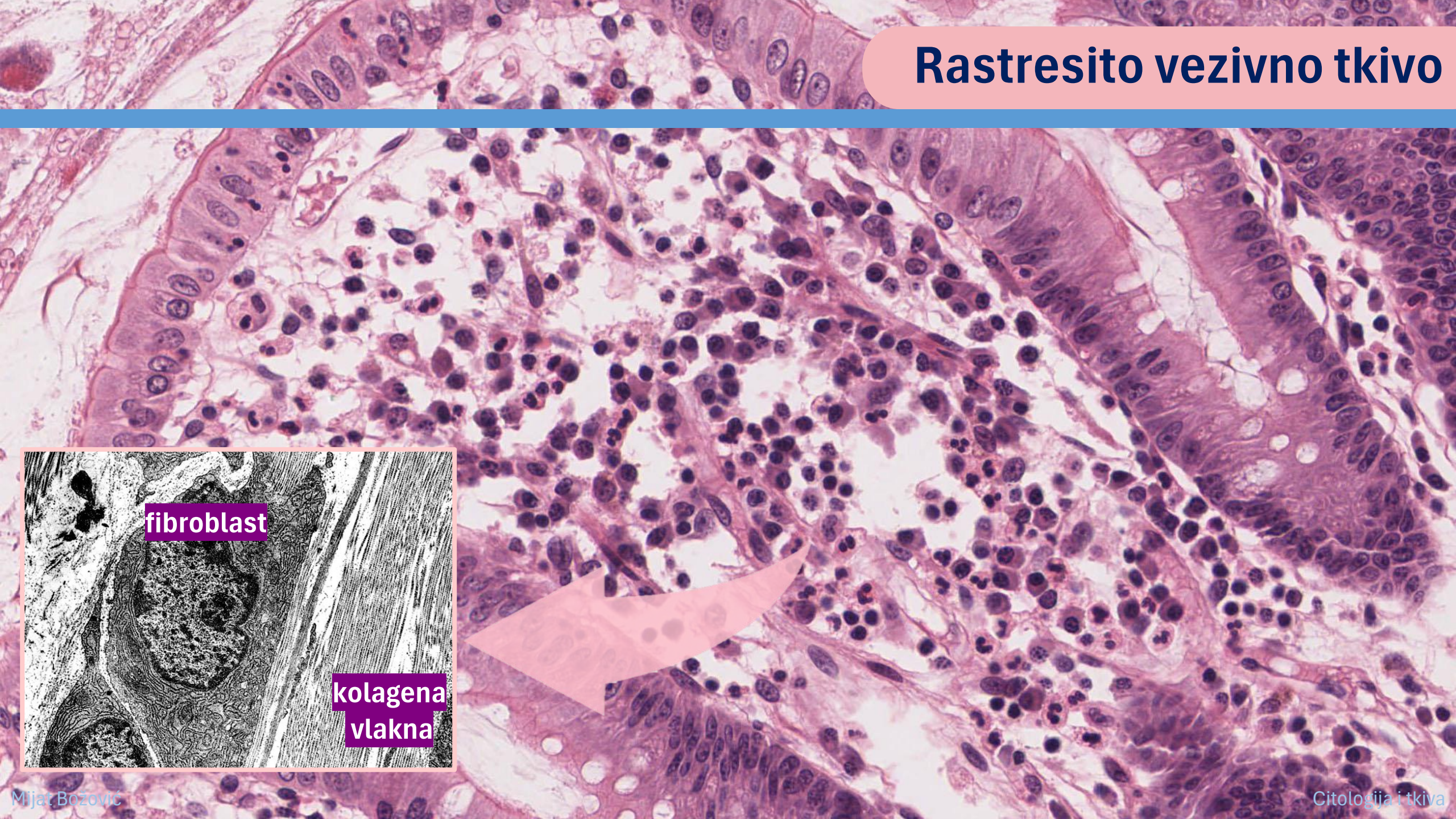
različite ćelije i
sva 3 tipa vlakana

kroz njega prolaze i krvni i
limfni sudovi i nervna vlakna

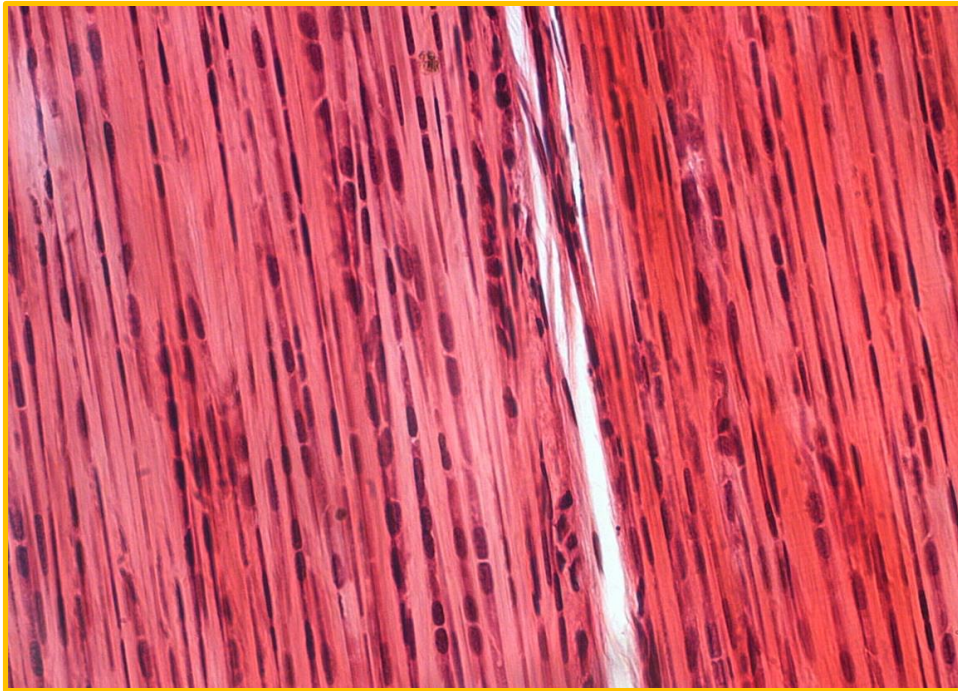
više funkcija u
organizmu

mehaničko-potporna, trofička i
transportna; depo vode i masti;
uloga u zapaljenjskim procesima

Rastresito vezivno tkivo



Textus connectivus compactus



tzv. fibrozno
vezivno tkivo

dominira **fibrozna** komponenta (**kolagena vlakna**) zbog čega je otpornije na mehaničke sile

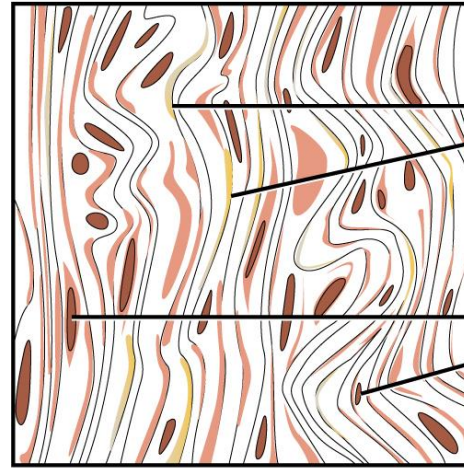
dominiraju
fibroblasti

srijeću se i **makrofagi** a osnovna supstanca je **redukovana**

2 tipa: iregularno
i regularno

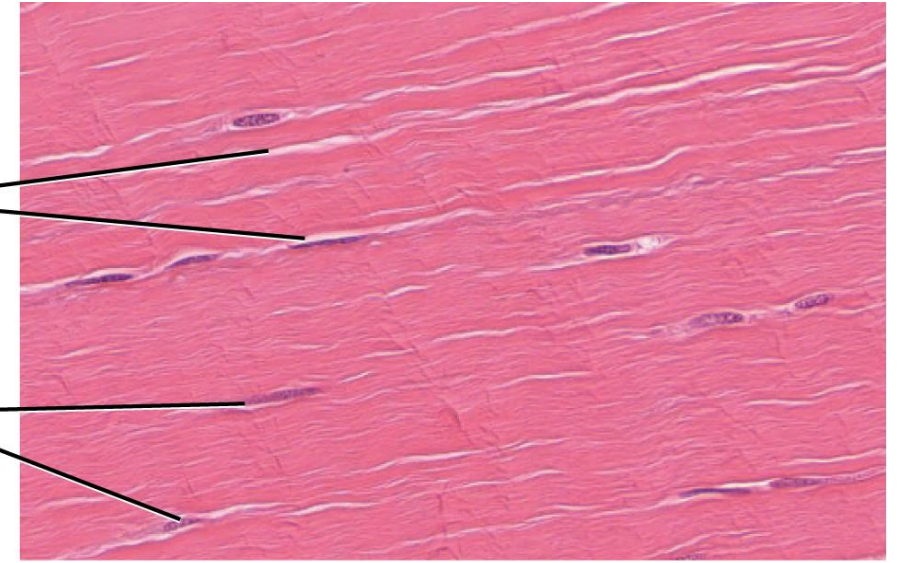
podjela u zavisnosti od toga kako su raspoređena vlakna (pravilno ili nepravilno)

regularno gusto
vezivno tkivo
(formirano)

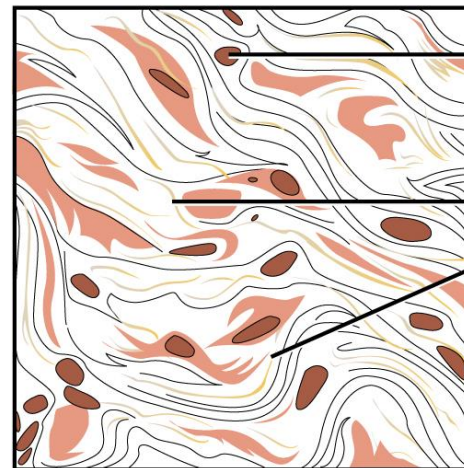


snopovi
kolagenih
vlakana

jedra
fibroblasta

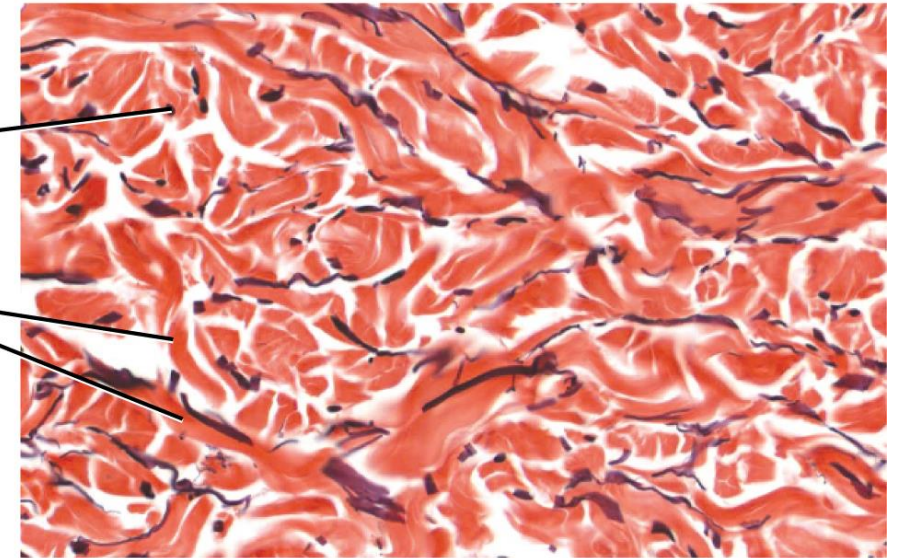


iregularno gusto
vezivno tkivo
(neformirano)

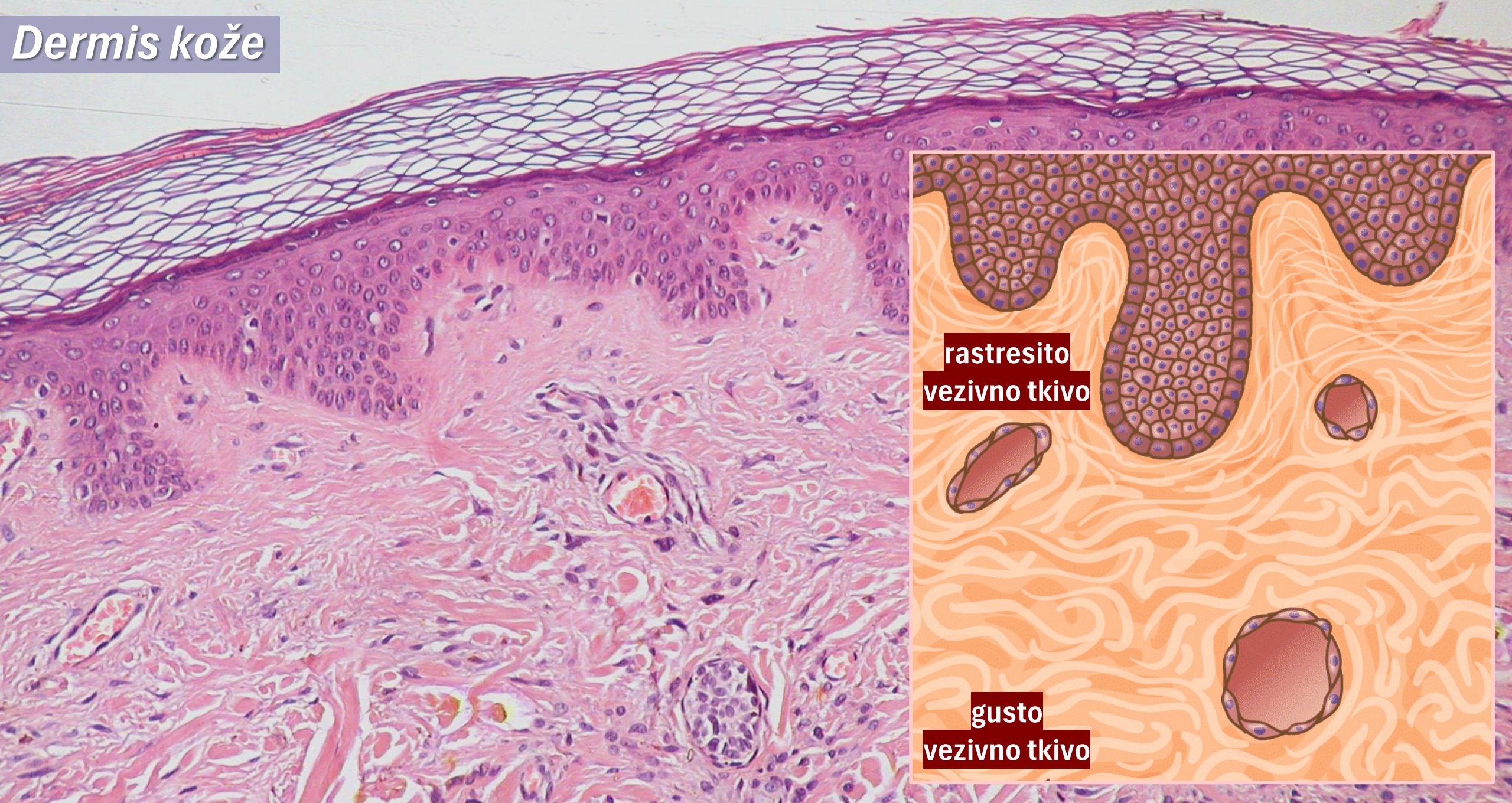


jedra
fibroblasta

snopovi
kolagenih
vlakana



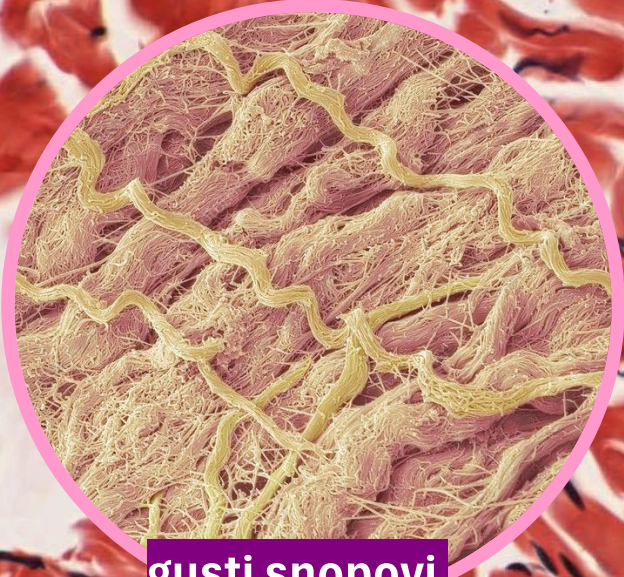Dermis kože



**rastresito
vezivno tkivo**

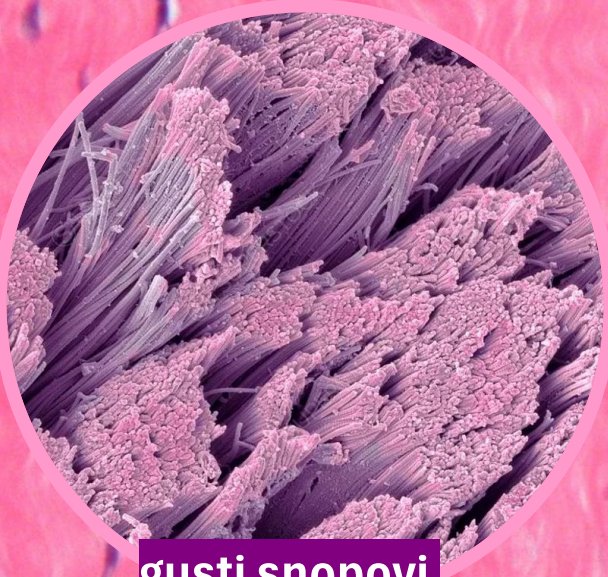**gusto
vezivno tkivo**

Gusto iregularno vezivno



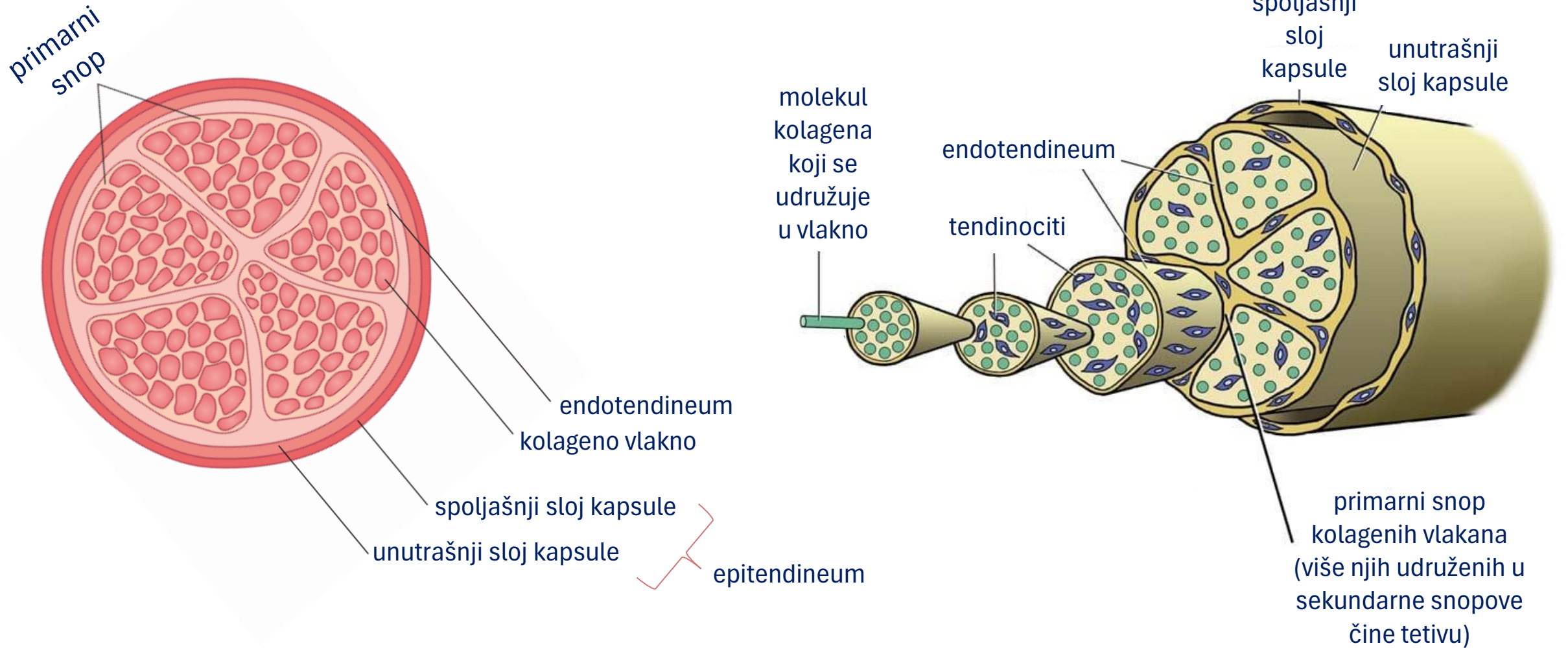
**gusti snopovi
kolagenih vlakana**

Gusto regularno vezivno

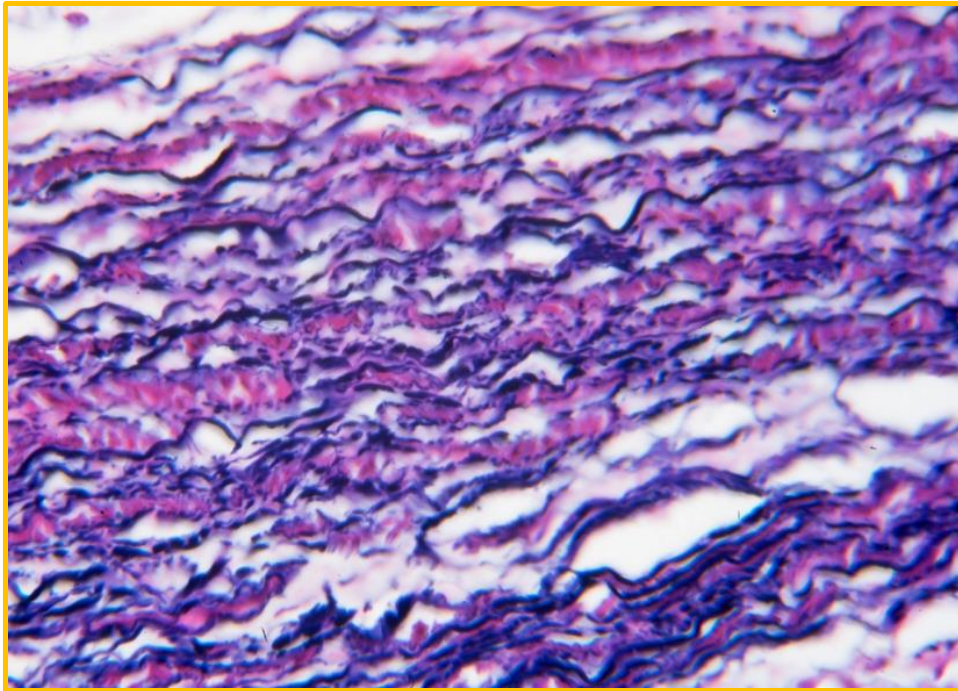


**gusti snopovi
kolagenih vlakana**

Tendo



Textus connectivus elasticus



različito se
klasifikuje

kao **podtip** gustog regularnog
ili kao **tip** gustog vezivnog tkiva

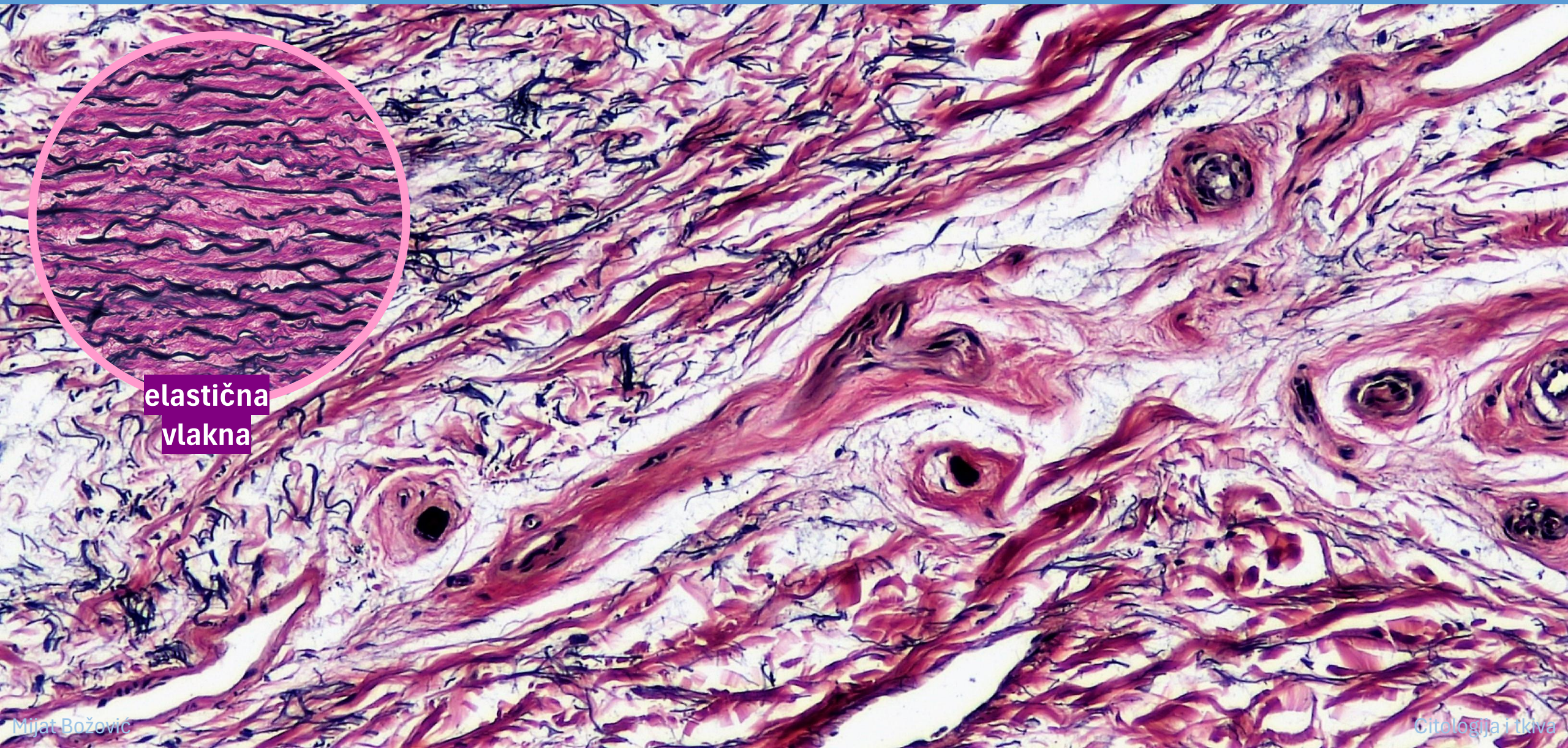
dominiraju
elastična vlakna

malo **osnovne supstance**,
tanka **kolagena vlakna** i rijetki,
spljošteni **fibroblasti**

rijetko zastupljeno
u organizmu

u nekim **ligamentima**
i u zidu velikih **arterija**

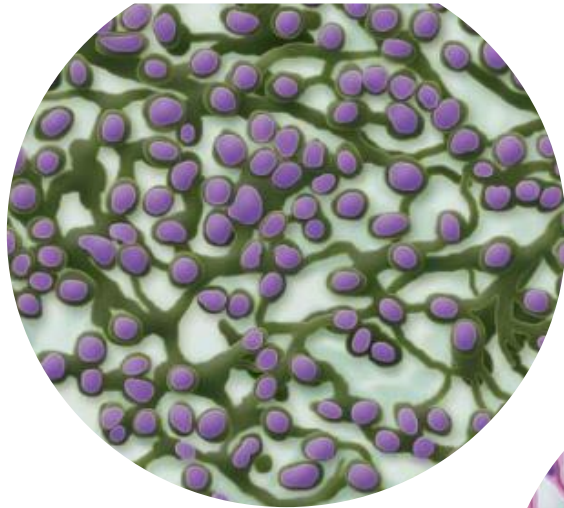
Elastično vezivno tkivo



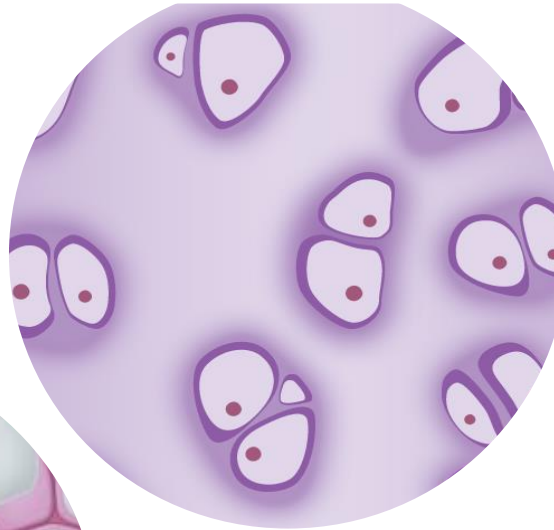
elastična
vlakna

B) Specijalizovana vezivna tkiva

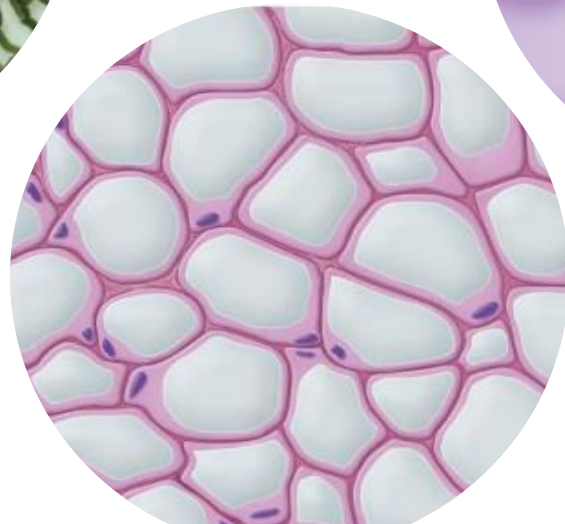
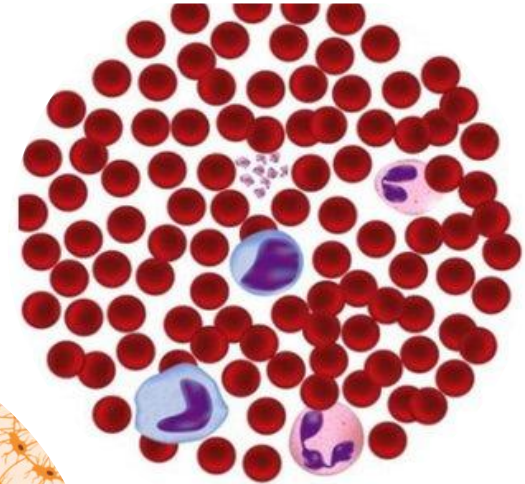
1. retikularno



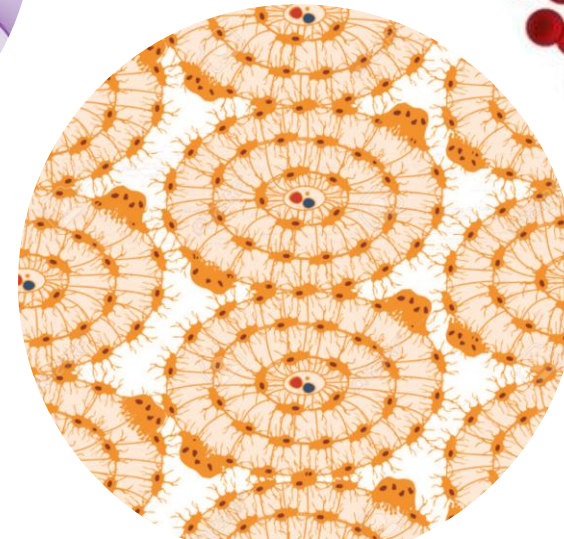
3. hrskavičavo



5. krv

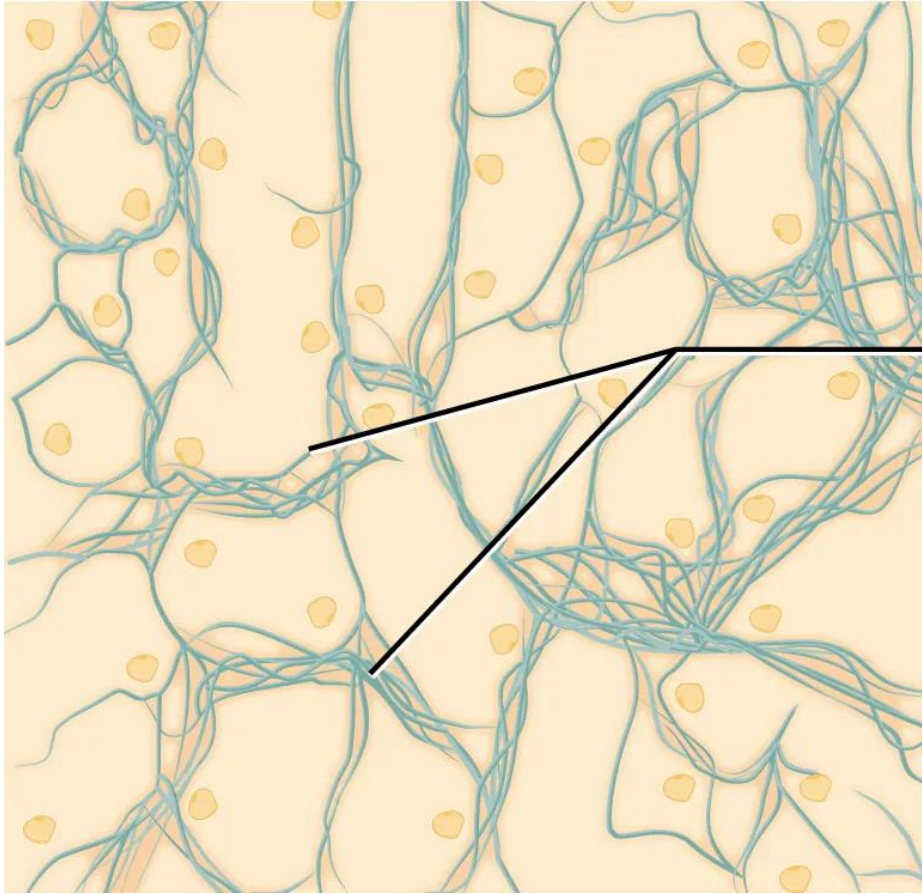


2. masno

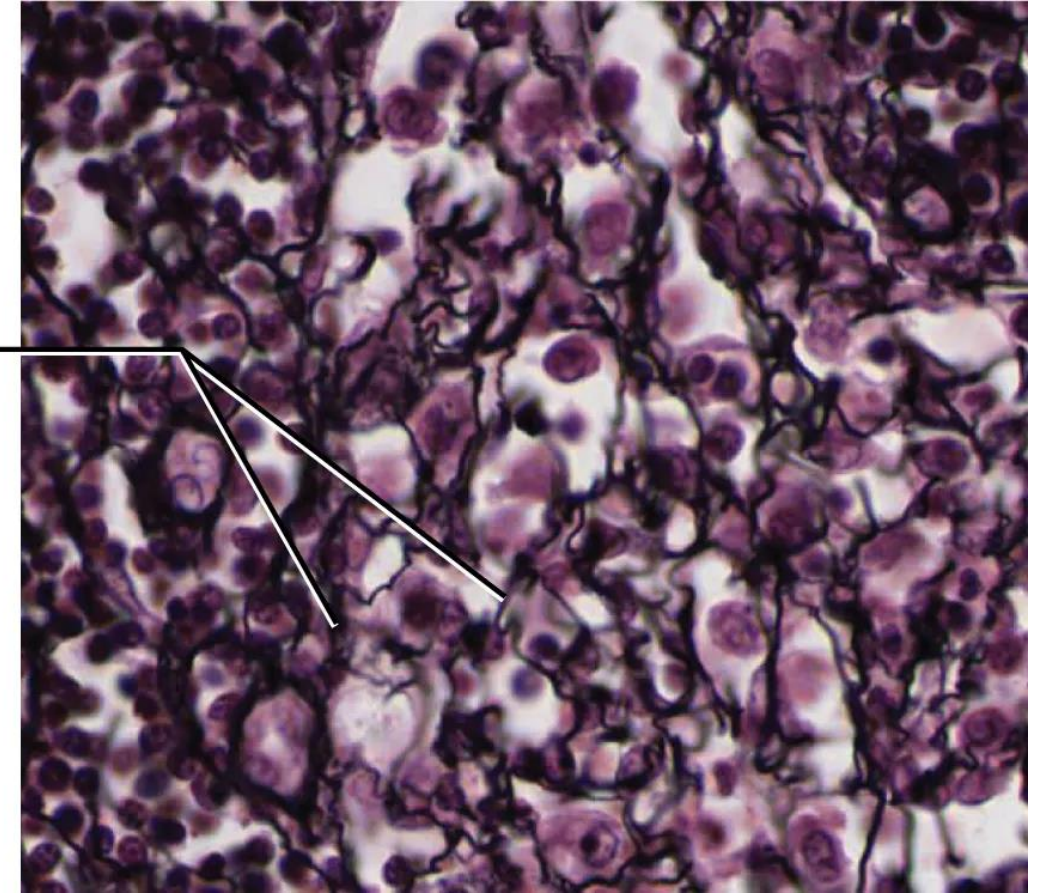


4. koštano

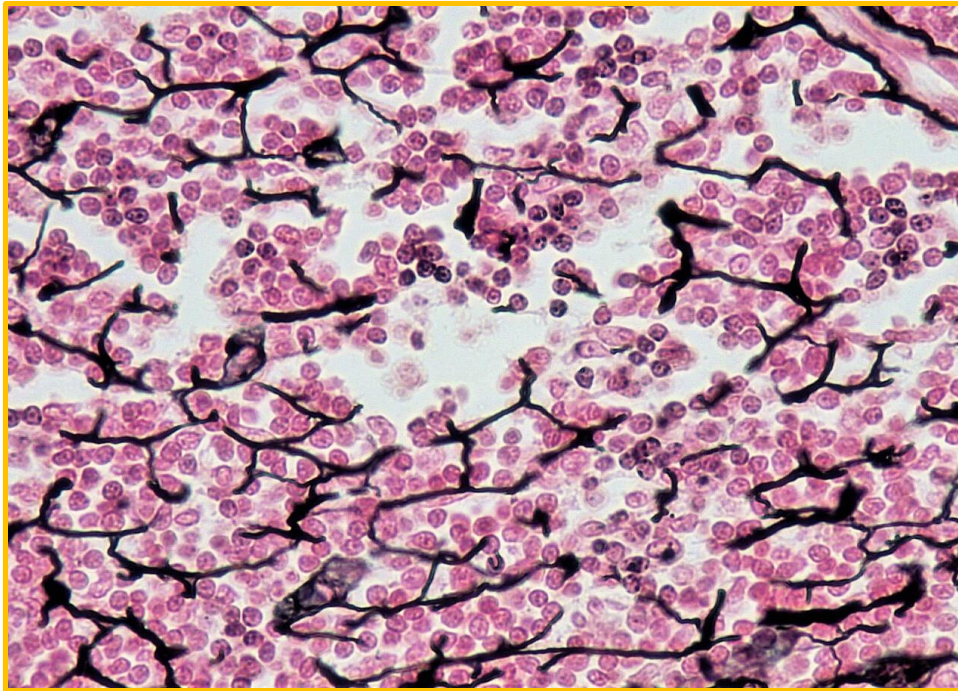
1. *Textus connectivus reticularis*



retikularna
vlakna



Osobine retikularnog tkiva



**citoretikulum i
fibrozni retikulum**

3D mreža retikularnih ćelija,
retikularnih vlakana i
osnovne supstance

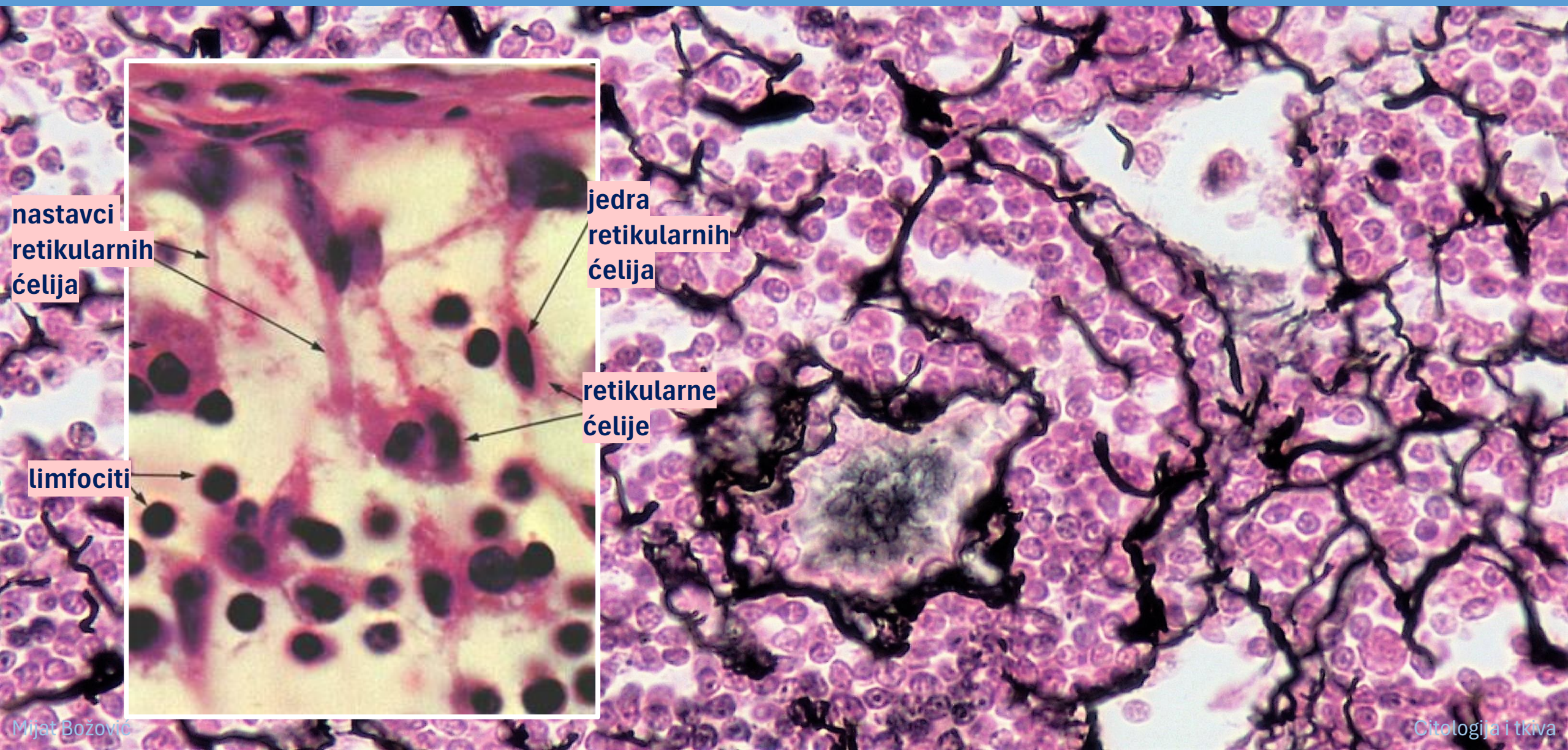
**fibroblasti, litoralne
i adventicijske ćelije**

retikularne ćelije su modifikovani
fibroblasti (proizvode kolagen tip
III); pored njih i ćelije koje imaju
sposobnost **fagocitoze**

**hematopoezno
i limfno tkivo**

retikularno tkivo čini **stromu**
hematopoeznih i limfnih organa

Retikularno vezivno tkivo



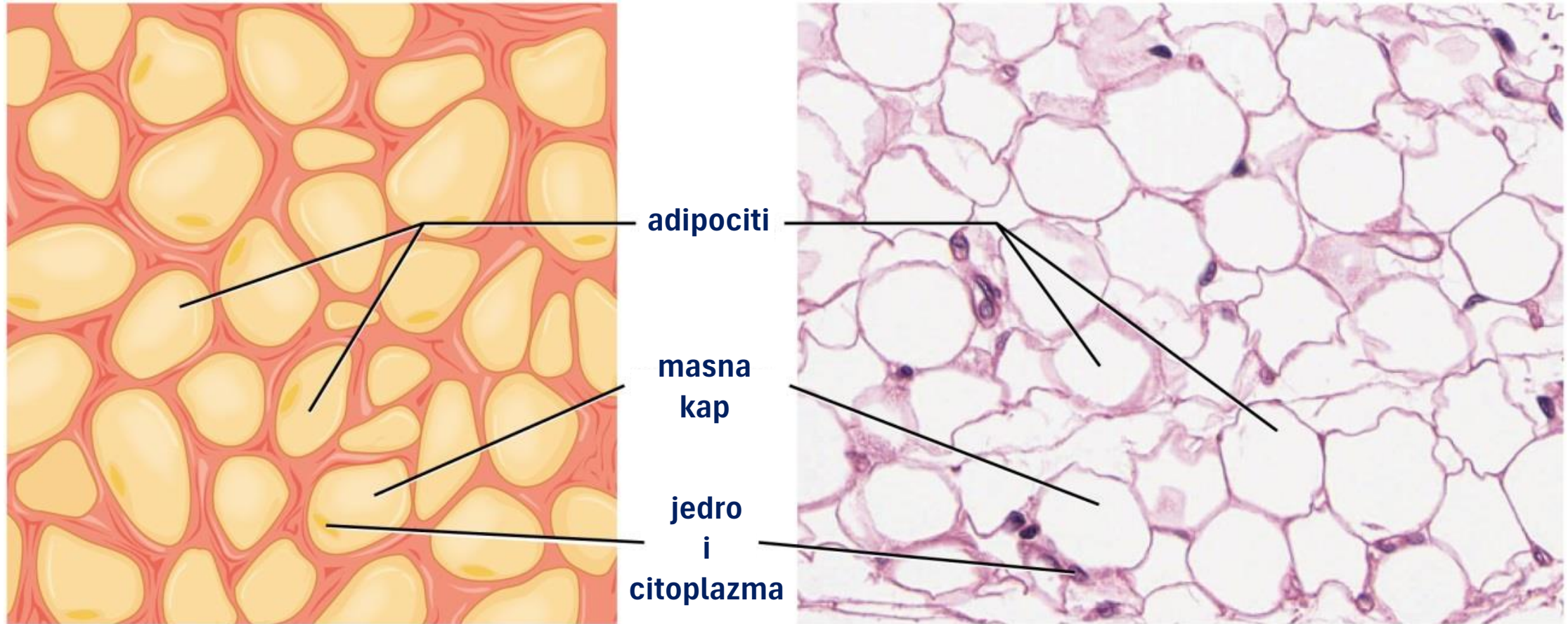
nastavci
retikularnih
ćelija

jedra
retikularnih
ćelija

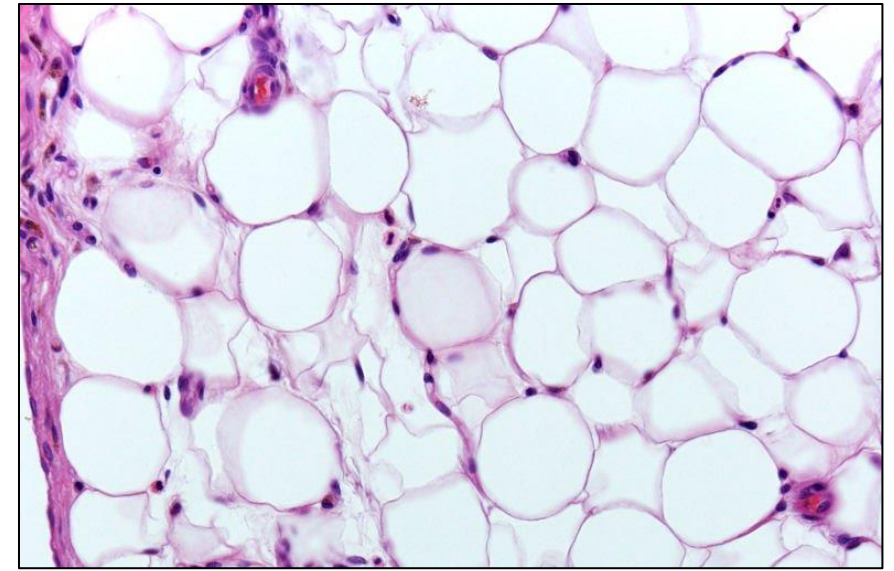
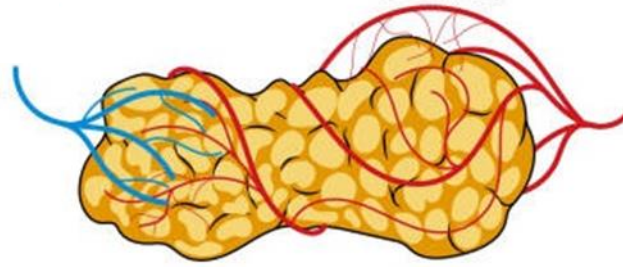

retikularne
ćelije

limfociti

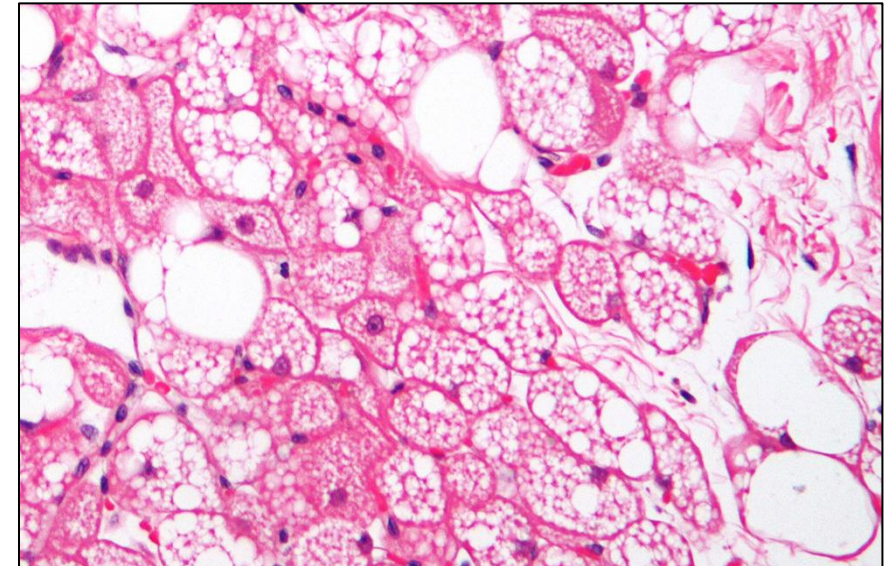
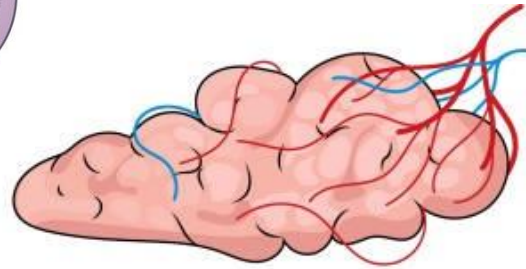
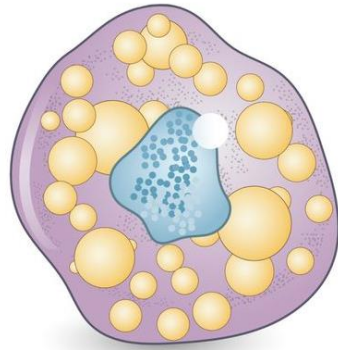
2. *Textus adiposus*



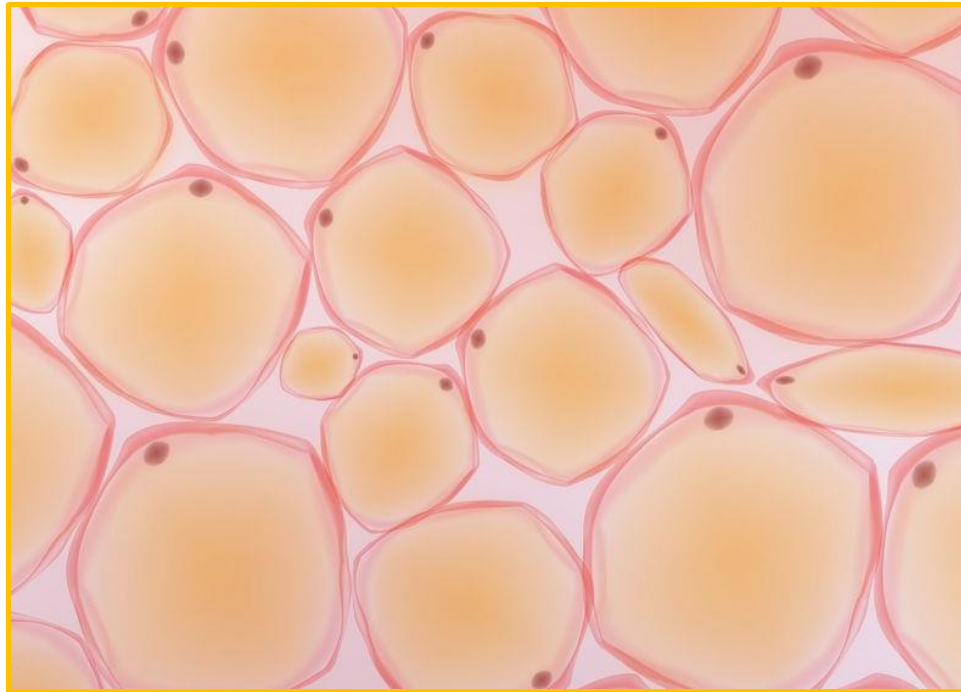
**bijelo, žuto ili
obično
(unilokusno)**



**mrko ili
ksantoadipozno
(multilokusno)**



Osobine masnog tkiva



za deponovanje
masti

kod odraslog muškarca
12-15% a kod žene 20-25%

dominiraju adipociti
a ECM je redukovan

masne ćelije (lipociti, adipociti)
su organizovane u veće ili
manje grupe

skladišno i
strukturno

skladišno proizvodi **energiju**
i služi za **termoizolaciju**,
strukturno ima **zaštitnu** i
potpornu ulogu

Textus adiposus albus

↑
jedro

← masna
kap →



**unilokularni adipocit
u finoj mreži
retikularnih vlakana**

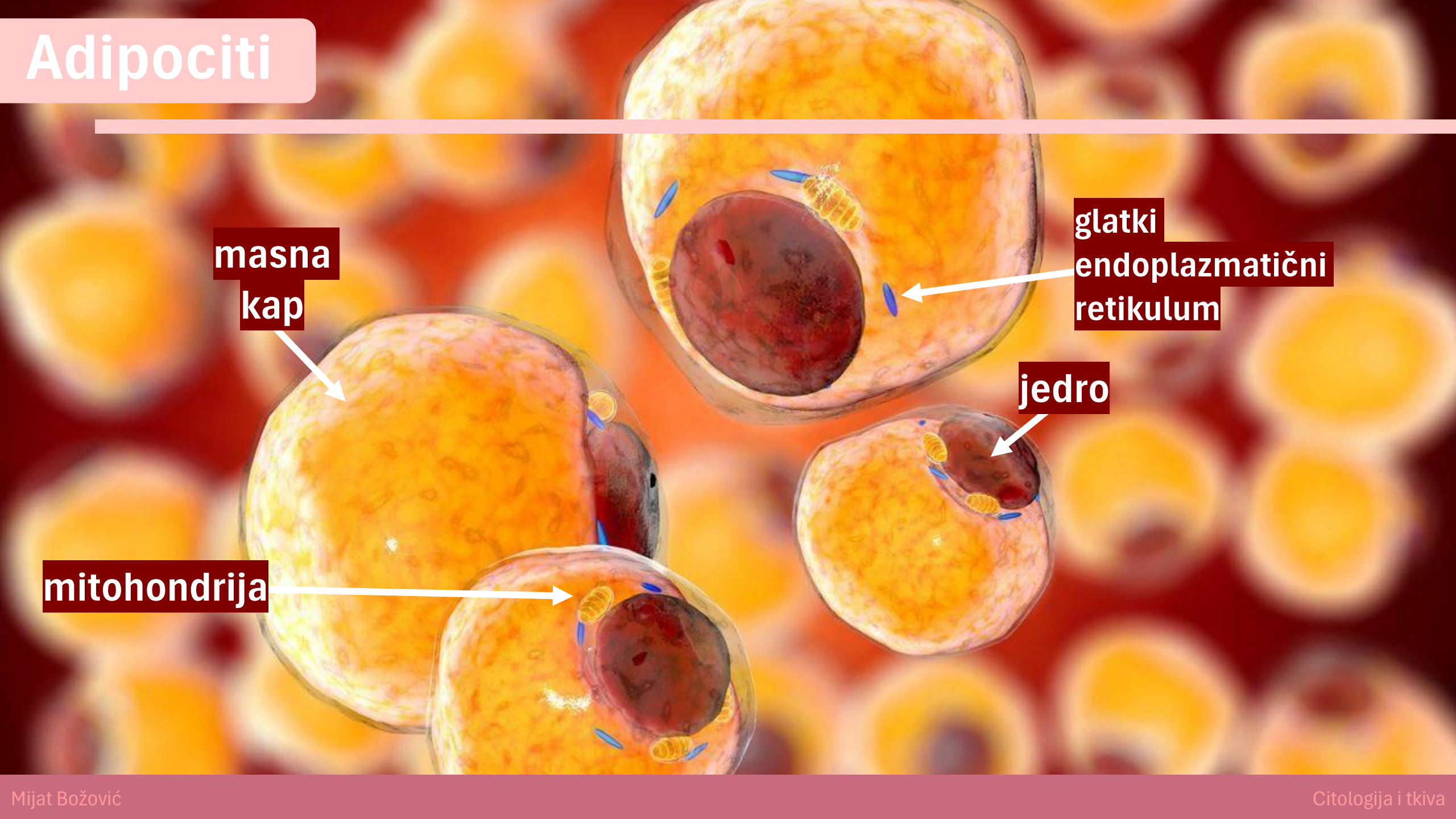
Adipociti

masna
kap

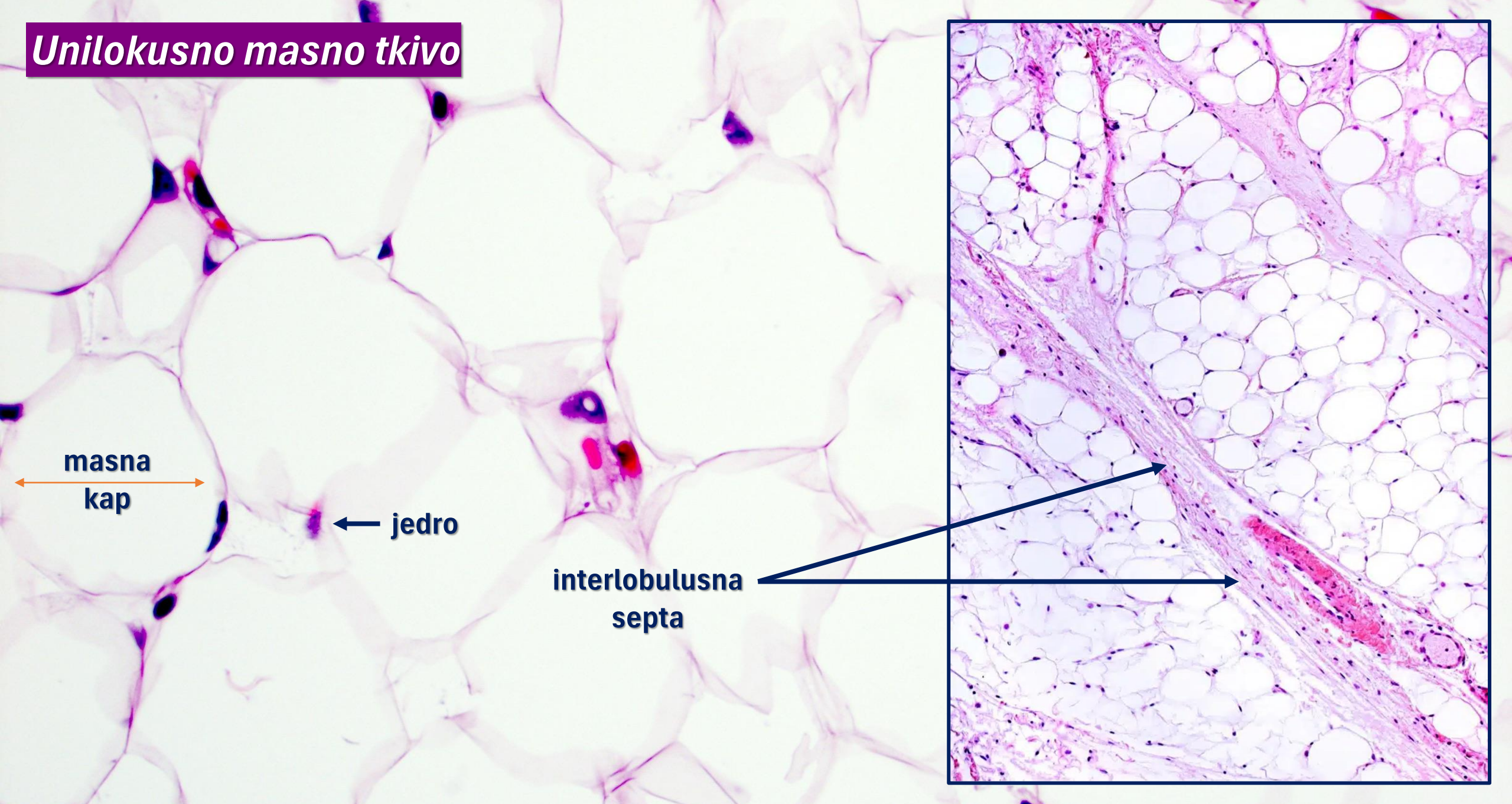
glatki
endoplazmatski
retikulum

jedro

mitohondrija



Unilokusno masno tkivo

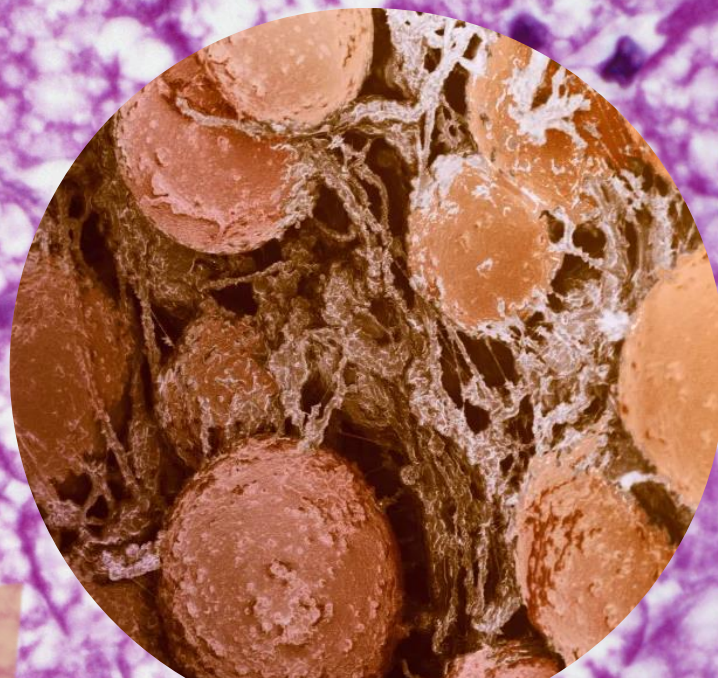
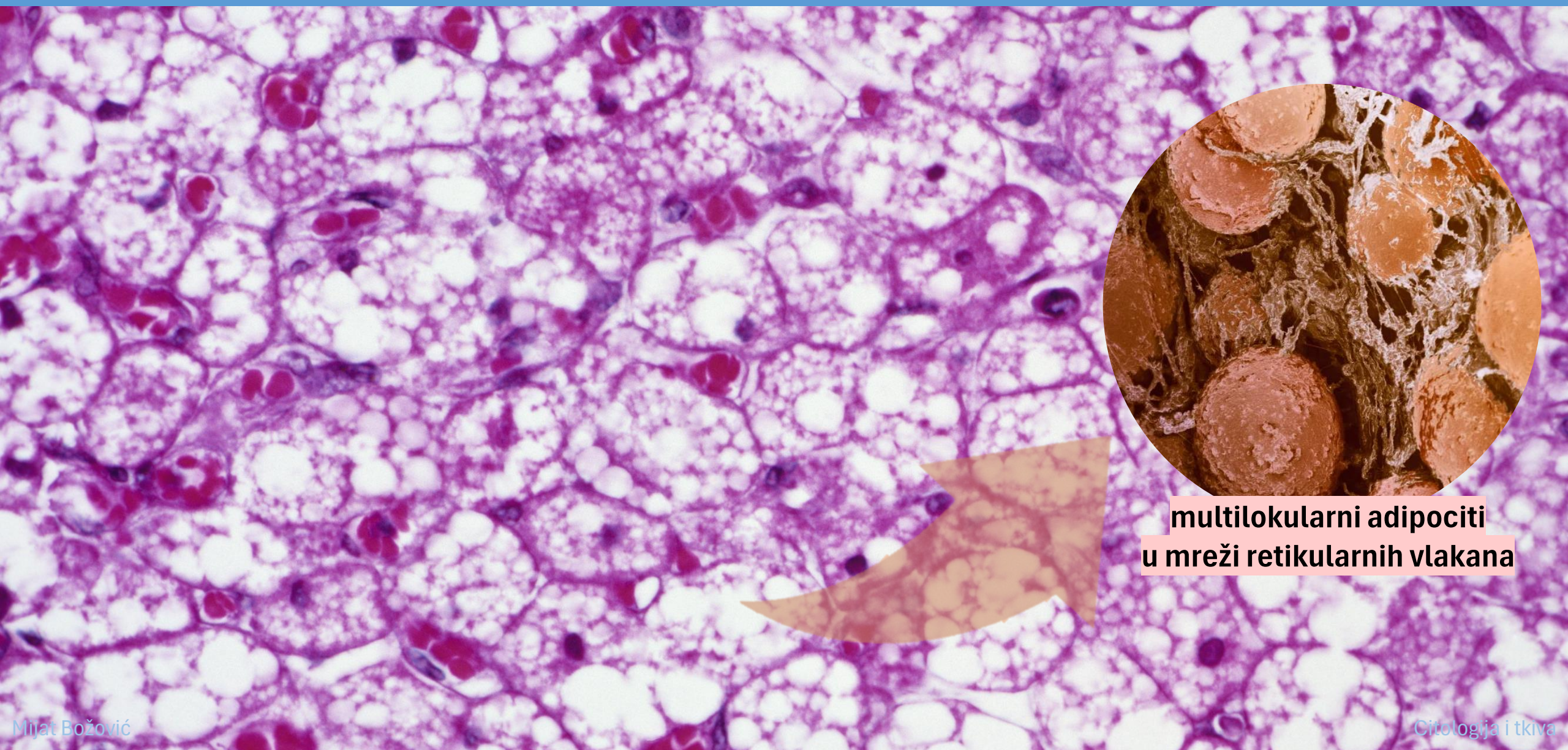


masna
kap

jedro

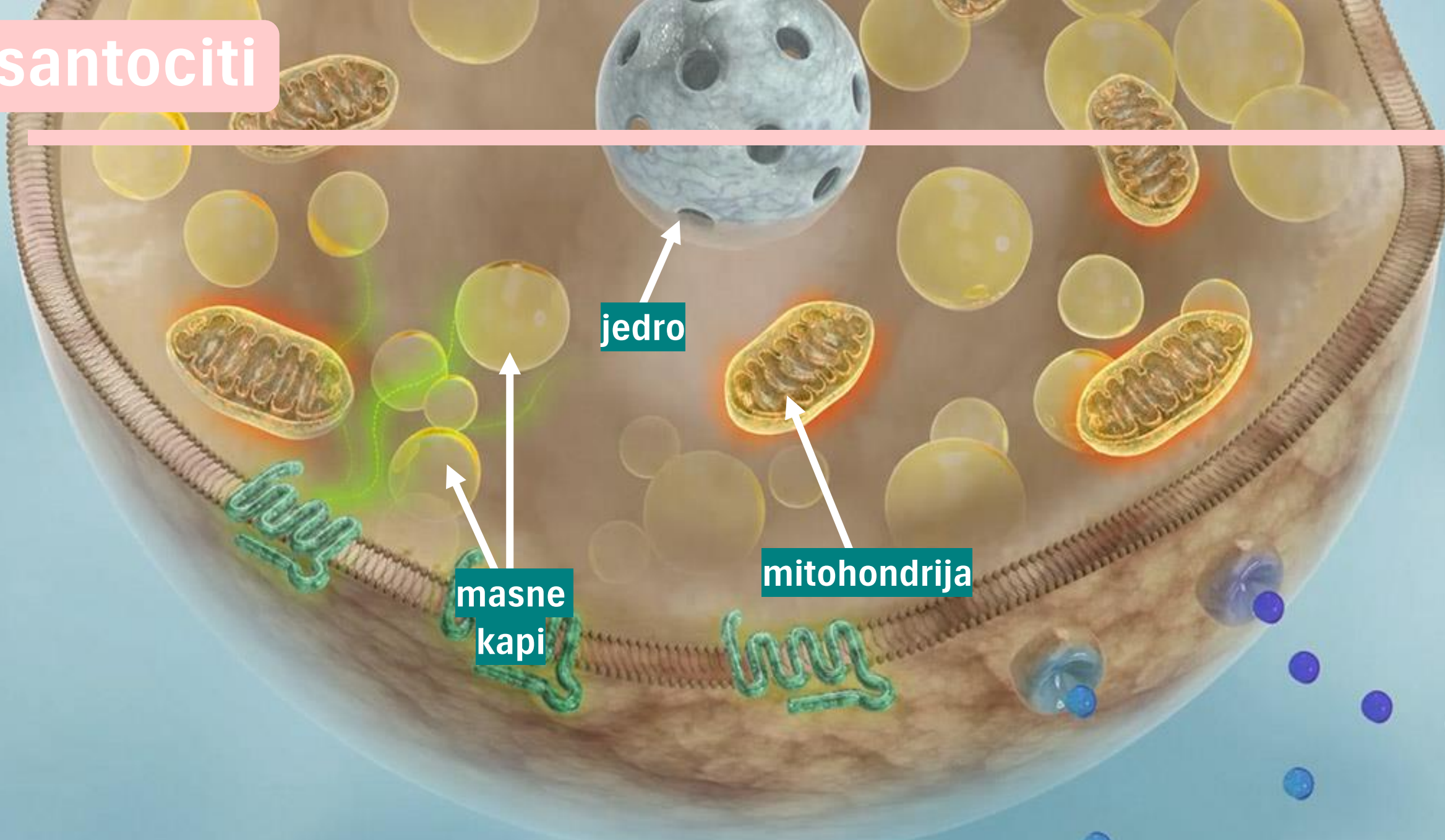
interlobulusna
septa

Textus adiposus fuscus



**multilokularni adipociti
u mreži retikularnih vlakana**

Ksantociti

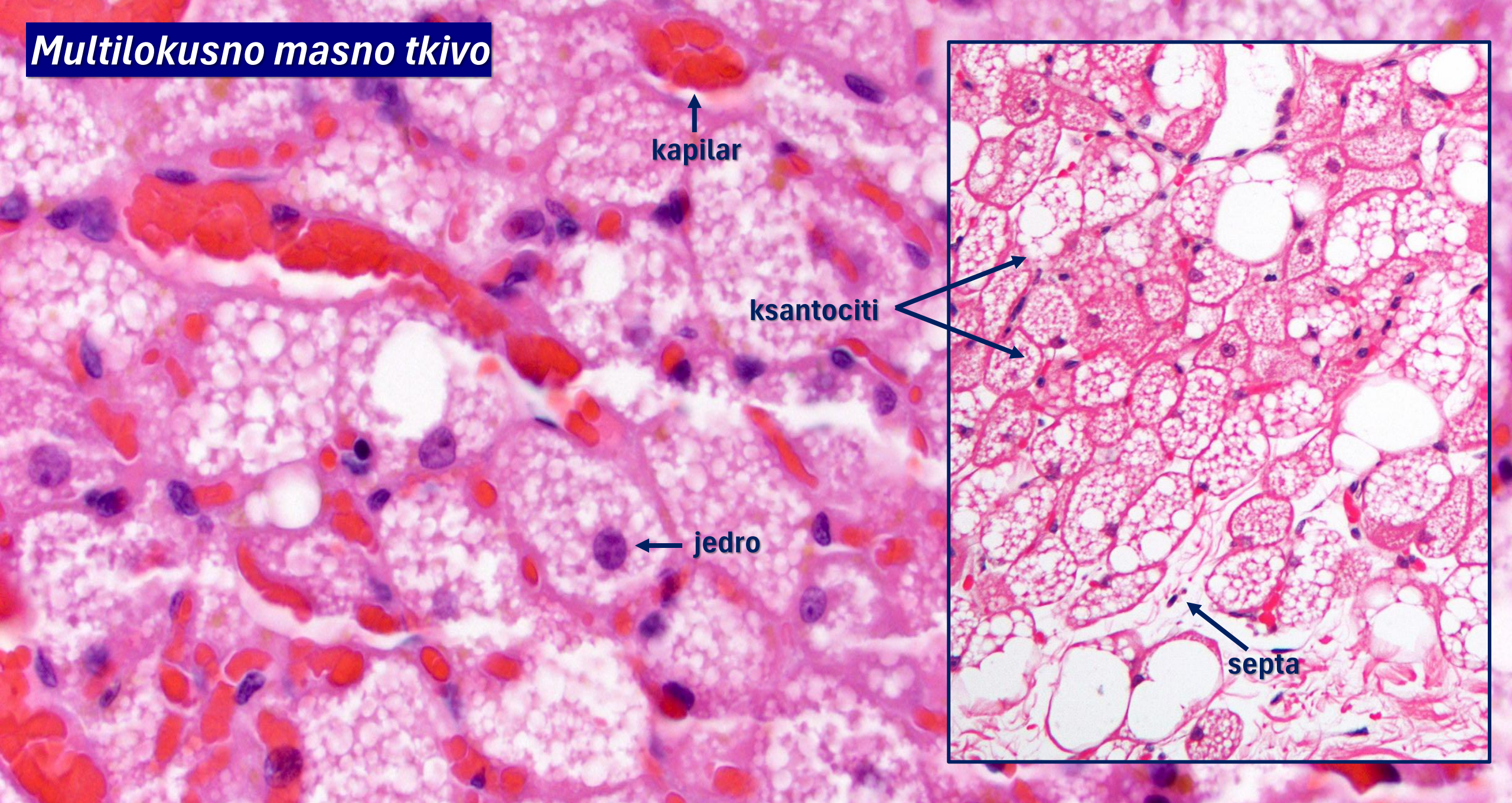


jedro

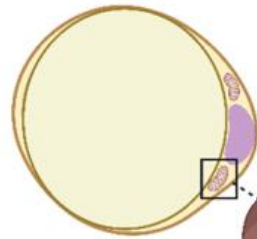
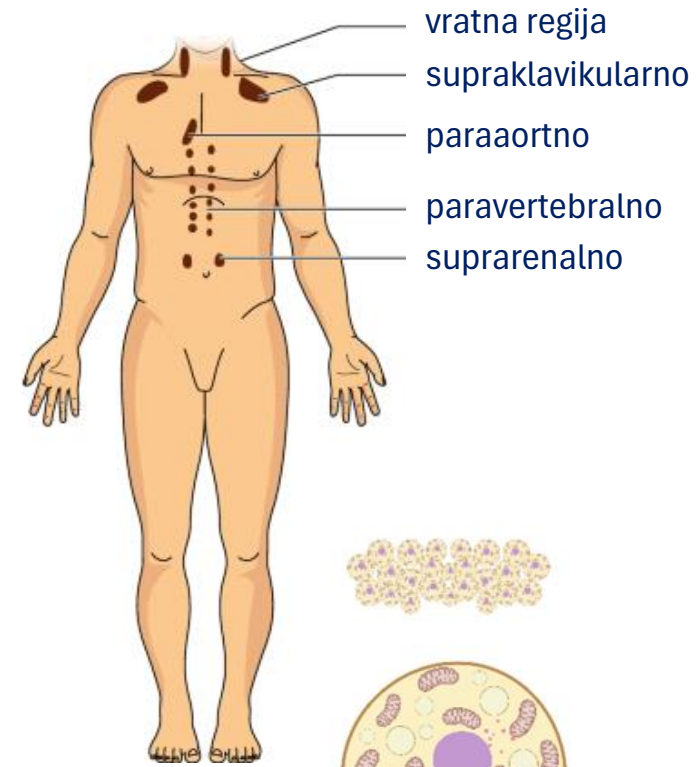
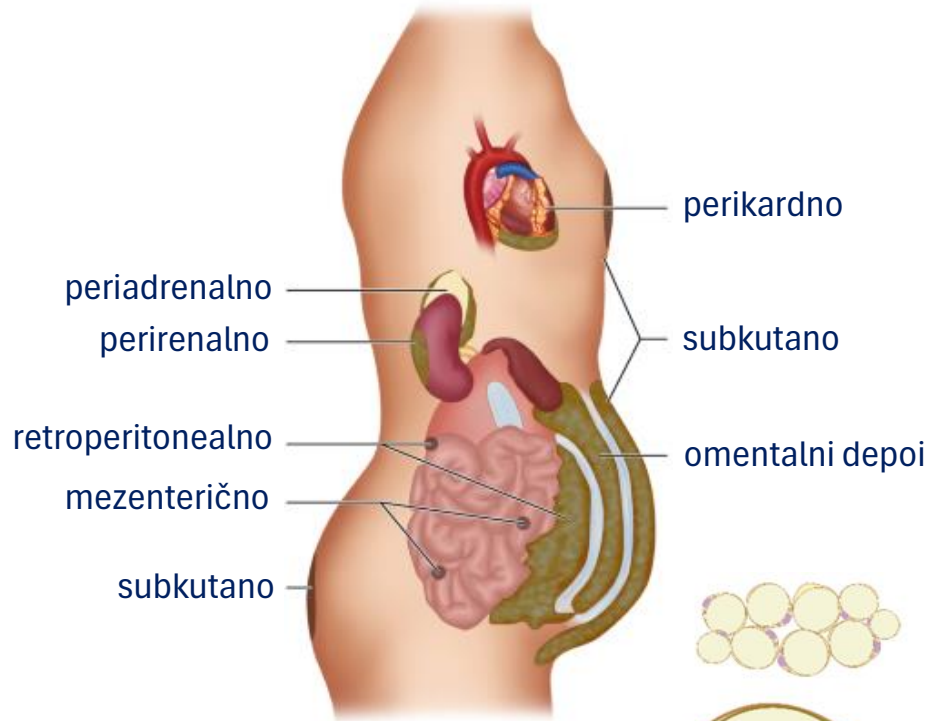
masne
kapi

mitohondrija

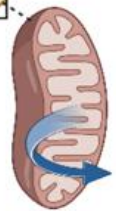Multilokusno masno tkivo



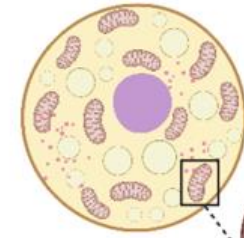
Lokalizacija i funkcije



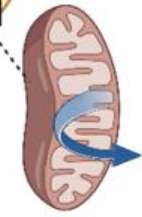
adipocit



produkcija energije

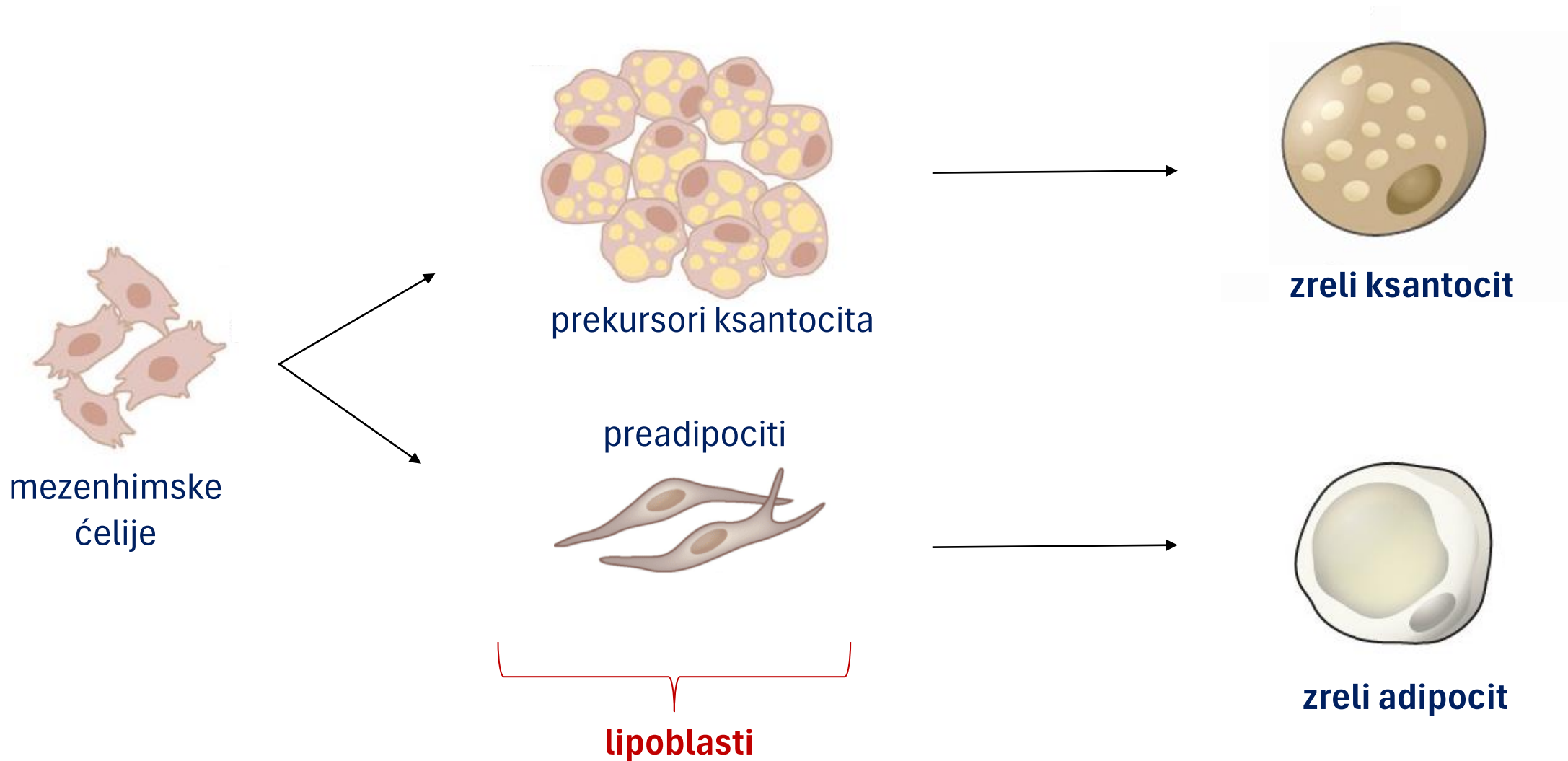


ksantocit

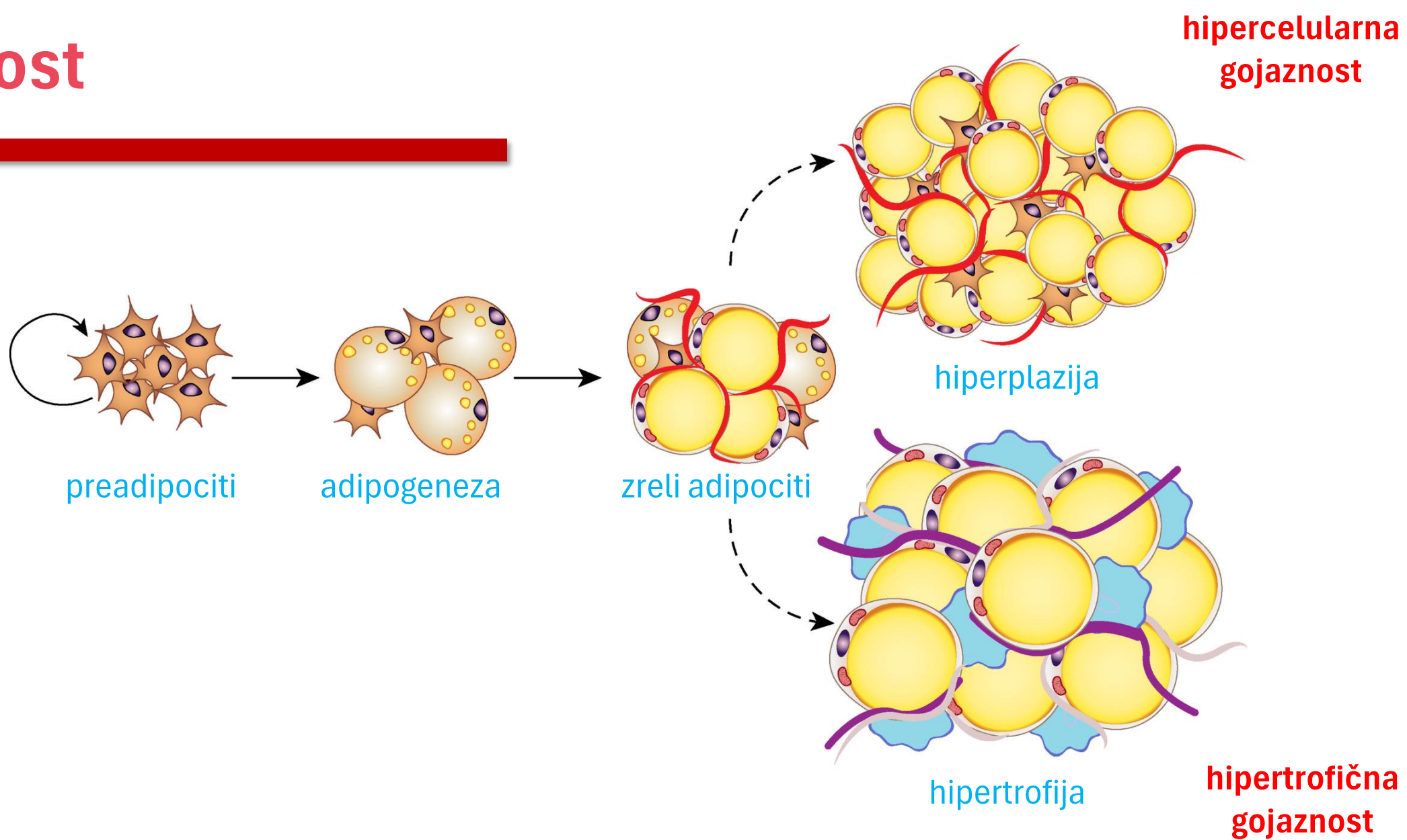


rasipanje energije (termogeneza)

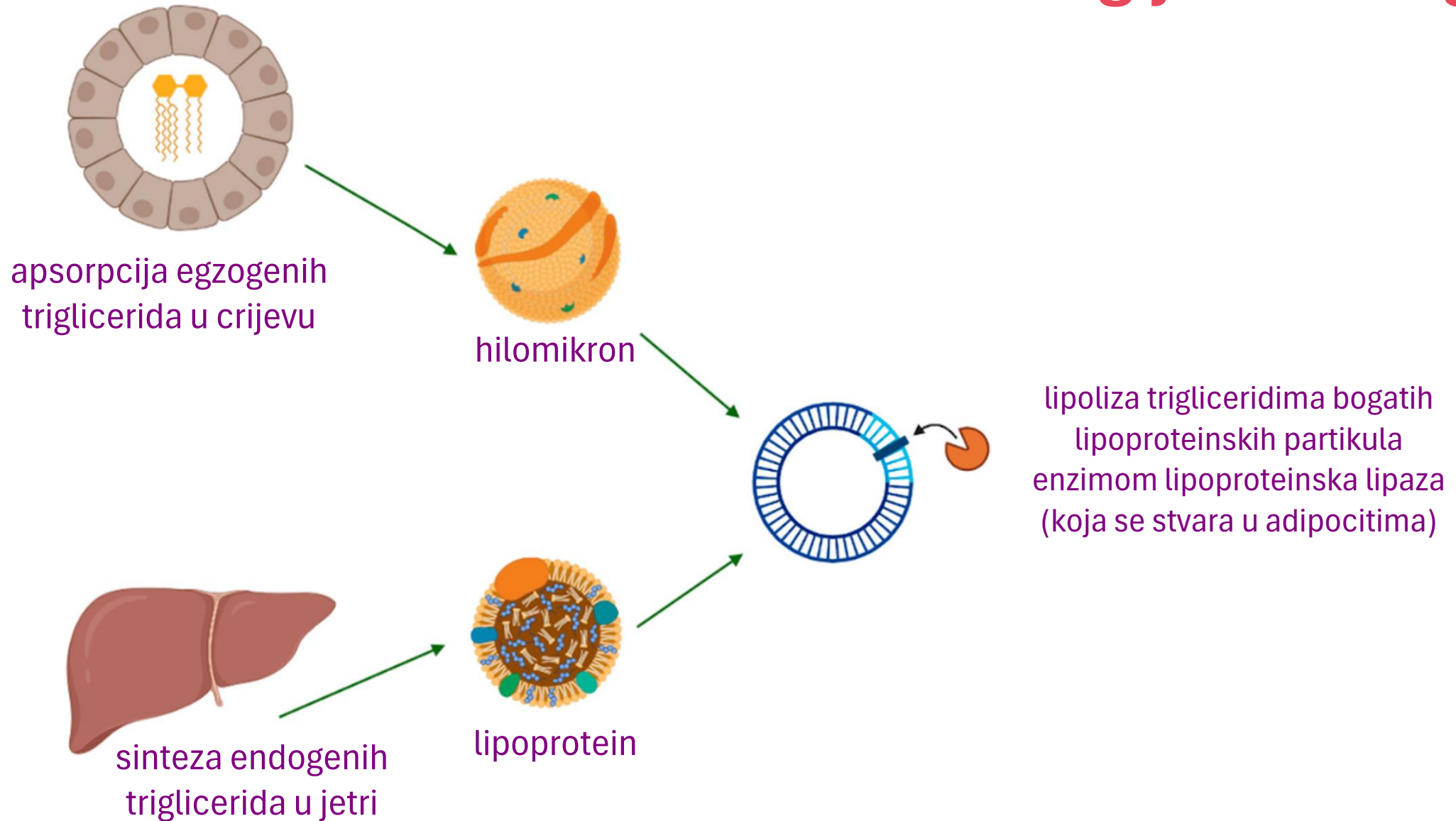
Adipogeneza



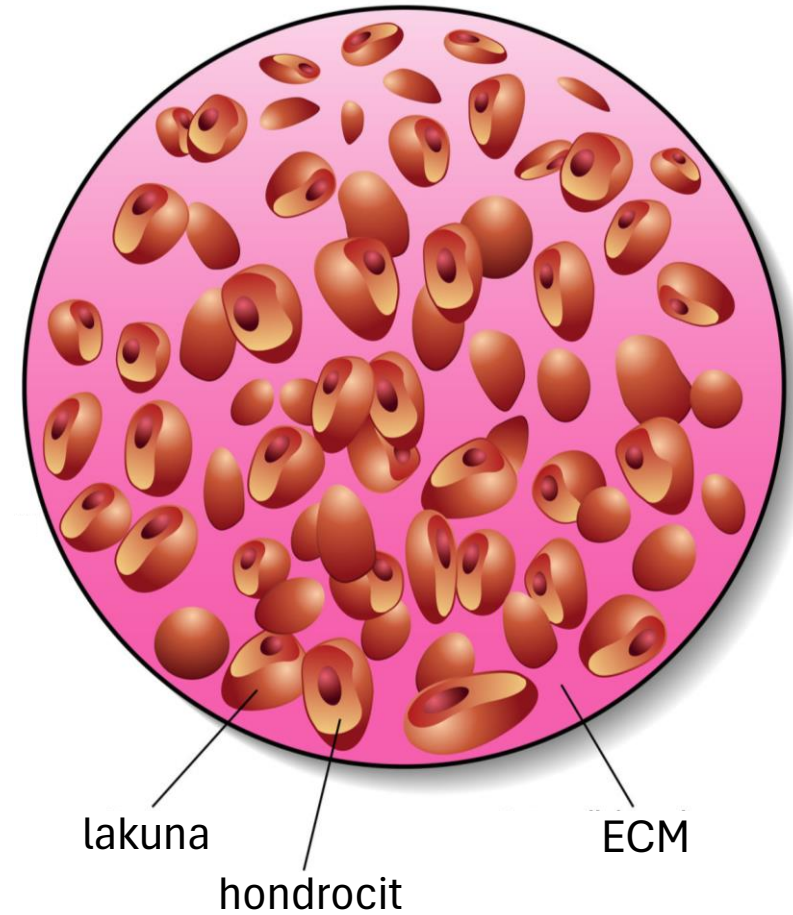
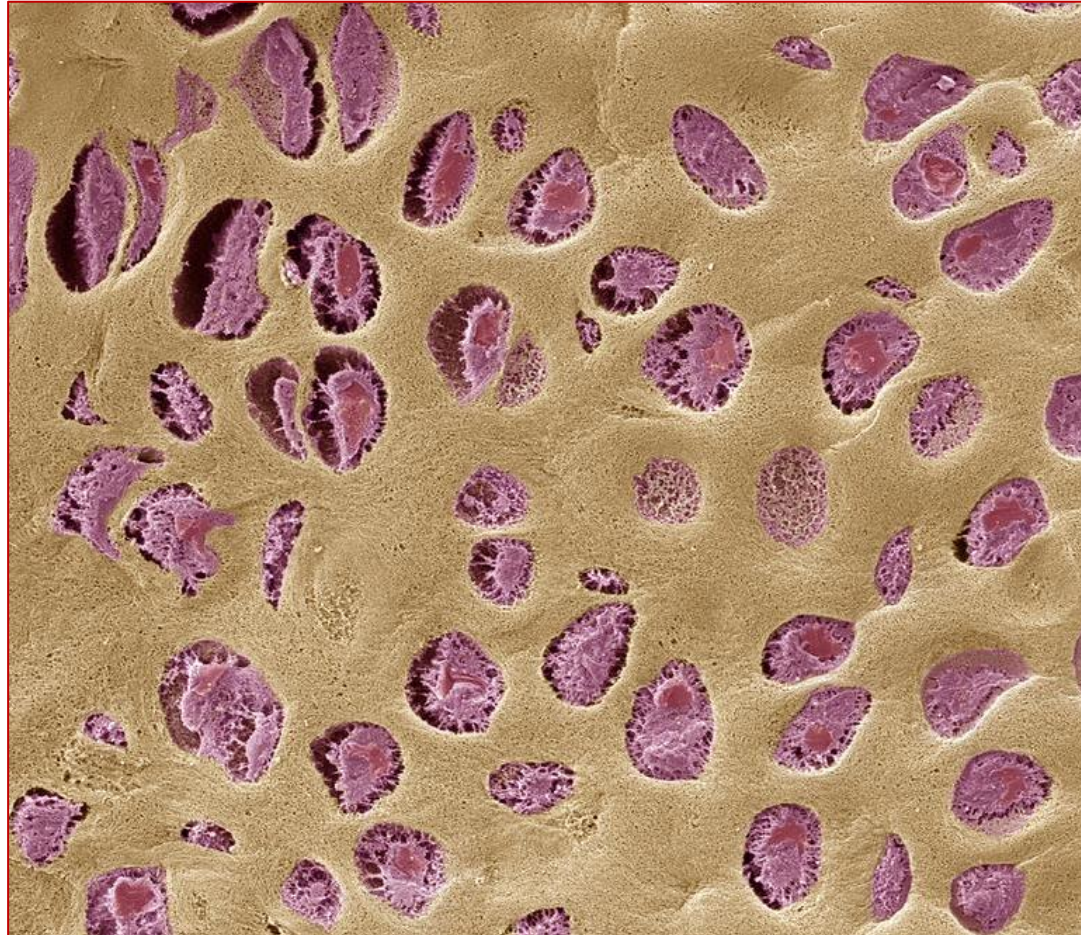
Gojaznost



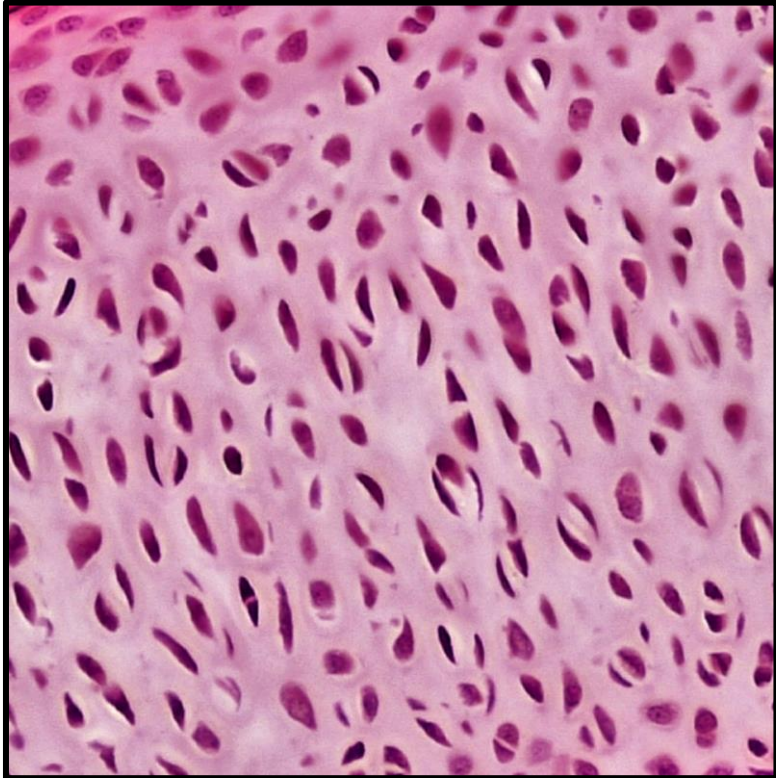
Histofiziologija masnog tkiva



3. *Textus cartilagineus*



Hrskavičavo tkivo



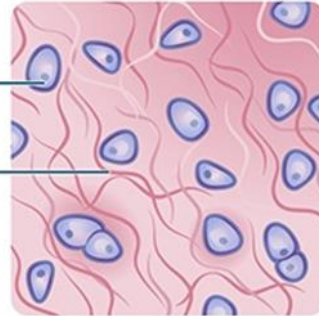
Osobine:

- ✓ Avaskularno (ne sadrži krvne i limfne sudove) potpuno vezivno tkivo sagrađeno od hondrocita i ECM; ne sadrži ni nervna vlakna.
- ✓ Funkcije: potpora mekim tkivima, amortizer (zglobna hrskavica) za kosti; značajna je za rast i razvoj dugih kostiju prije i poslije rođenja.
- ✓ Ishrana hrskavice se odvija difuzijom kiseonika i hranljivih materija iz okolnog veziva (perihondrijuma) ili iz sinovijalne tečnosti (kod zglobova) i krvnih sudova kosti.
- ✓ ECM je čvrst i čine ga kolagena i/ili elastična vlakna i osnovna supstanca bogata glikozaminoglikanima i proteoglikanima.

Tipovi hrskavice

hondrocit

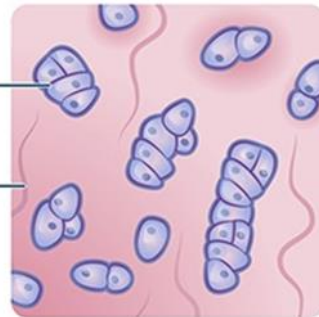
ECM sa kolagenim (II tip)
i elastičnim vlaknima



ELASTIČNA HRSKAVICA

hondrocit

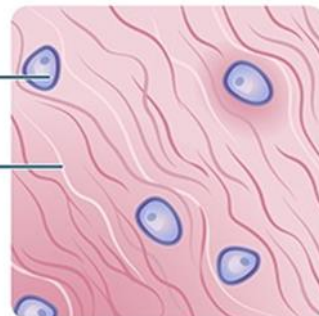
ECM sa kolagenim
vlaknima (II tip)



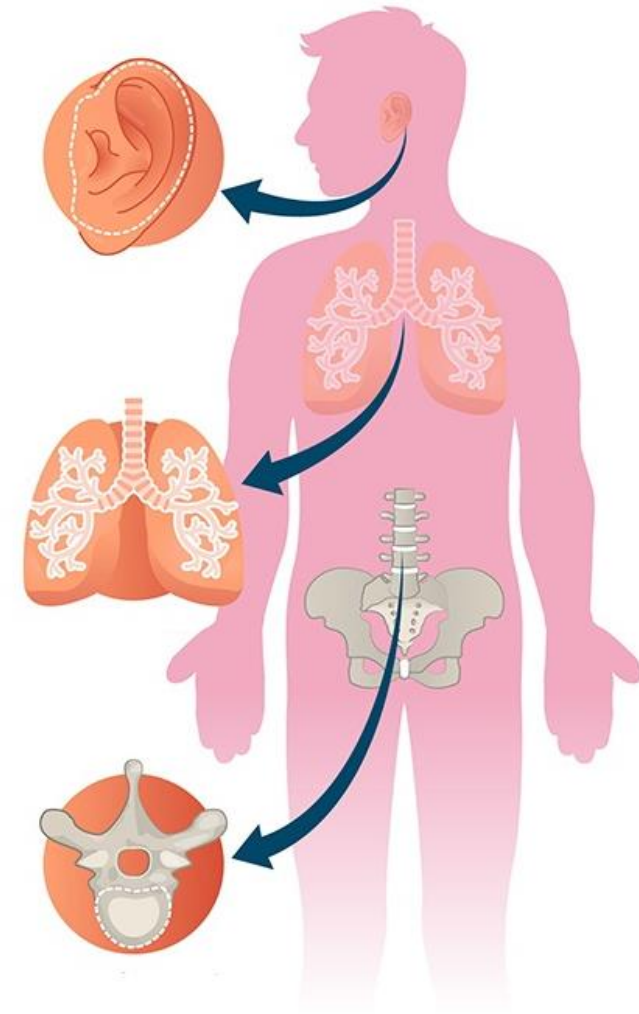
HIJALINA HRSKAVICA

hondrocit

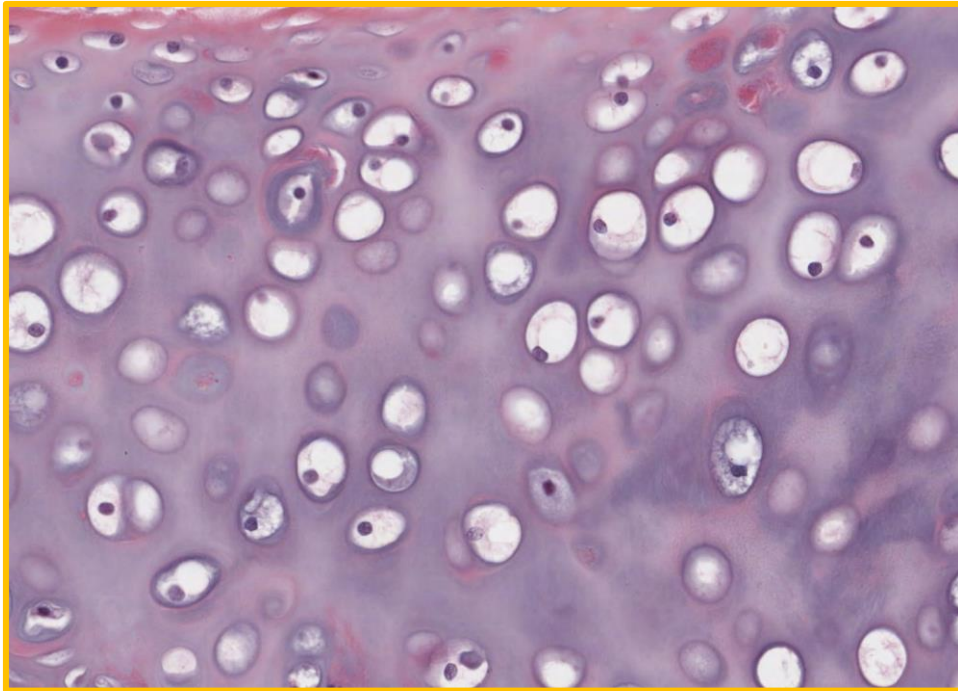
ECM sa velikom količinom
snopova kolagenih vlakana (I tip)



FIBROZNA HRSKAVICA



Cartilago hyalinis



najzastupljenija
u organizmu

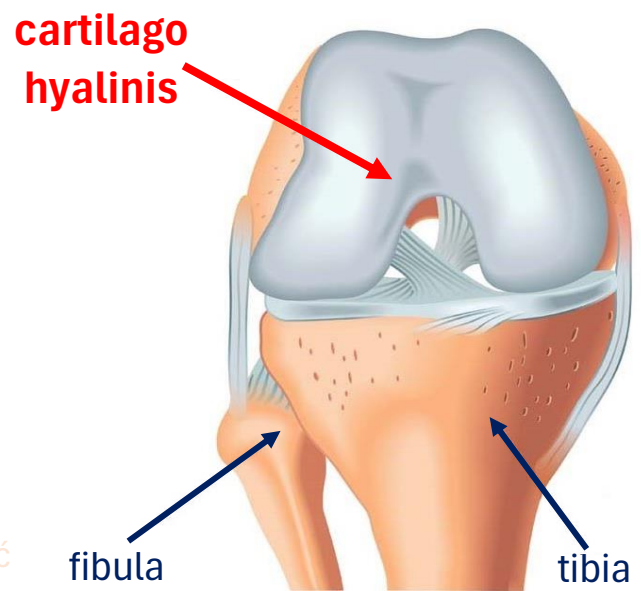
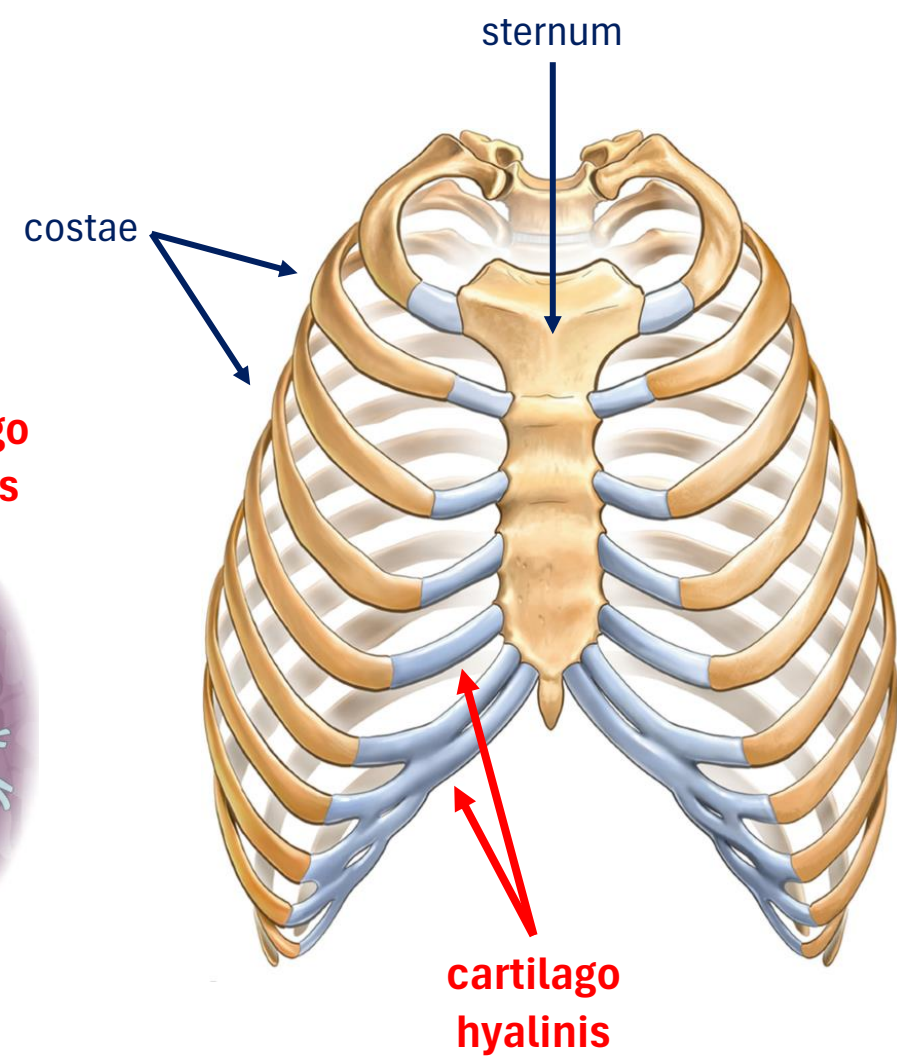
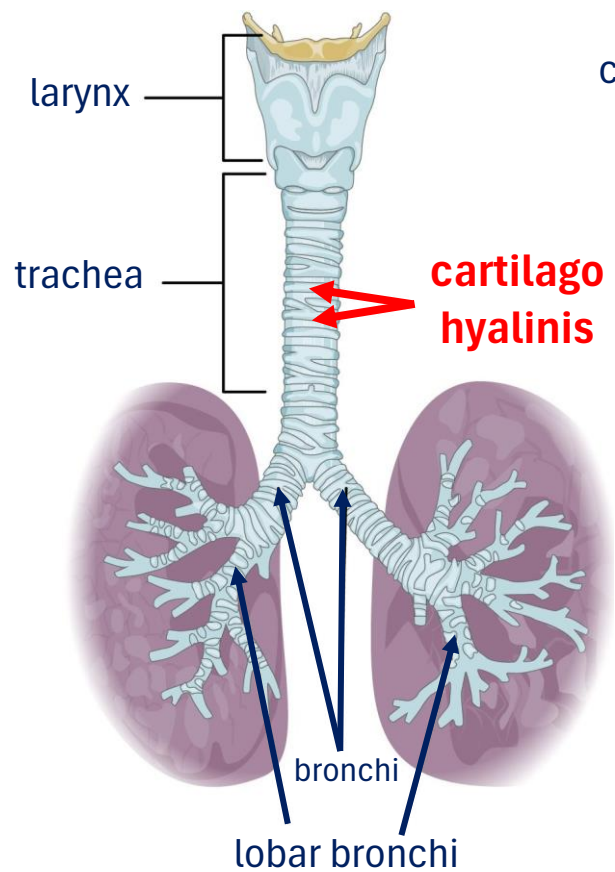
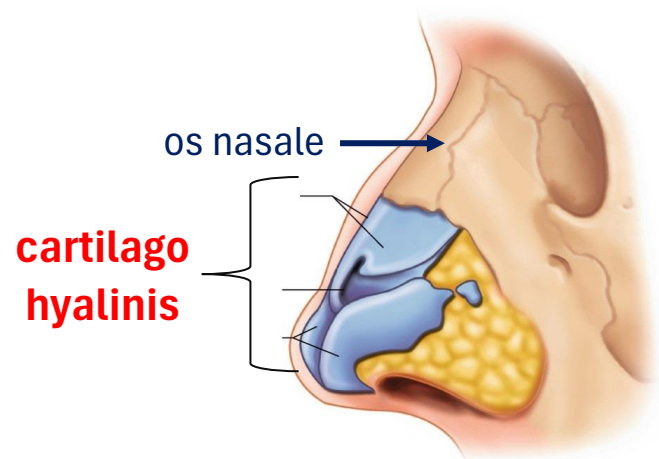
staklastog izgleda

grč. *hyalos* – staklo; svježa je
plavkasto-bijela i providna

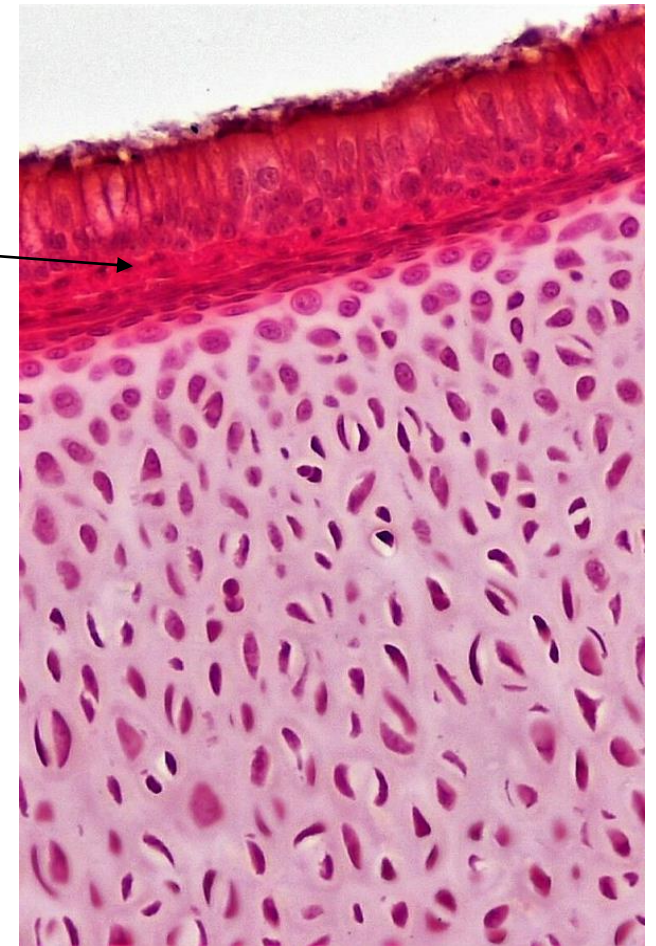
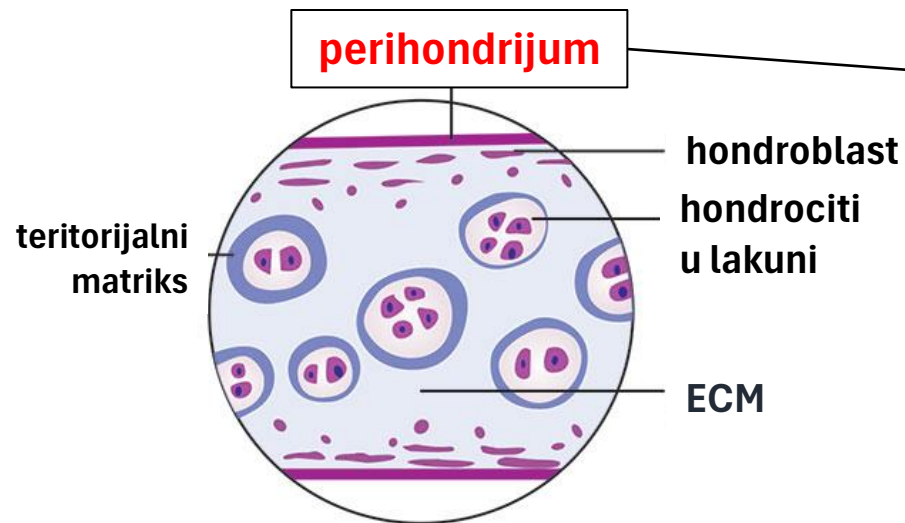
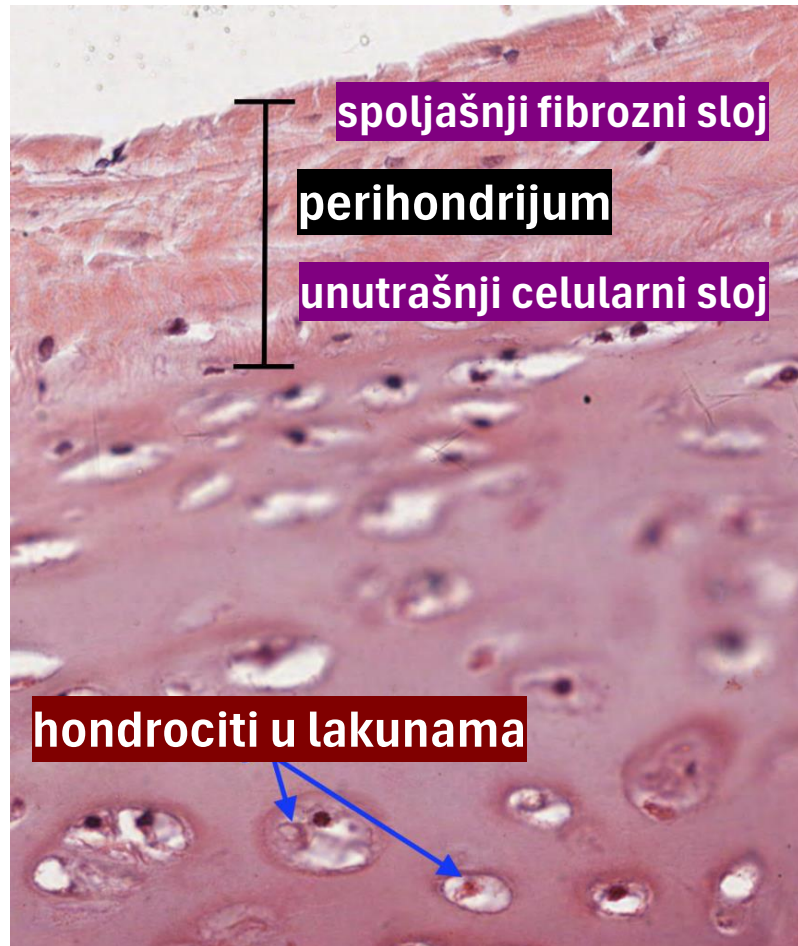
čini veći dio
skeleta embriona

privremenog karaktera:
postpuno i najvećim dijelom
se zamjenjuje koštanim tkivom

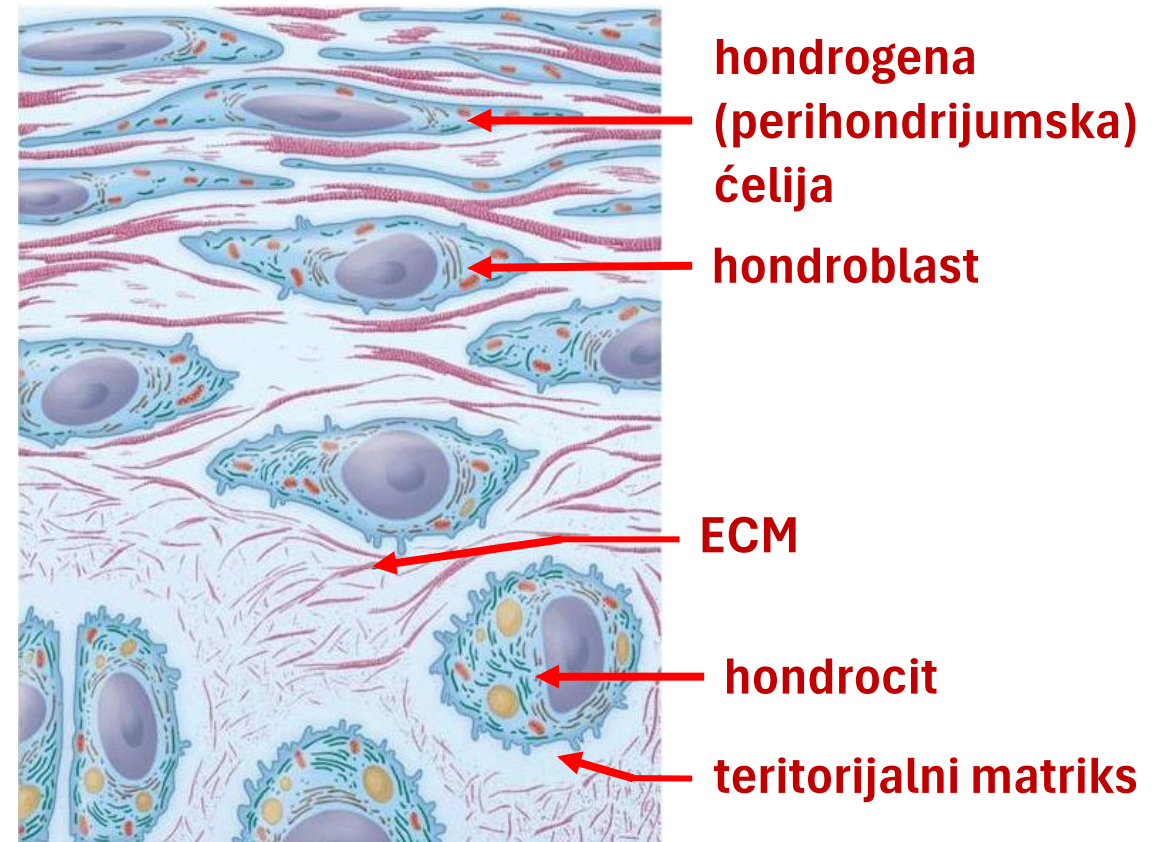
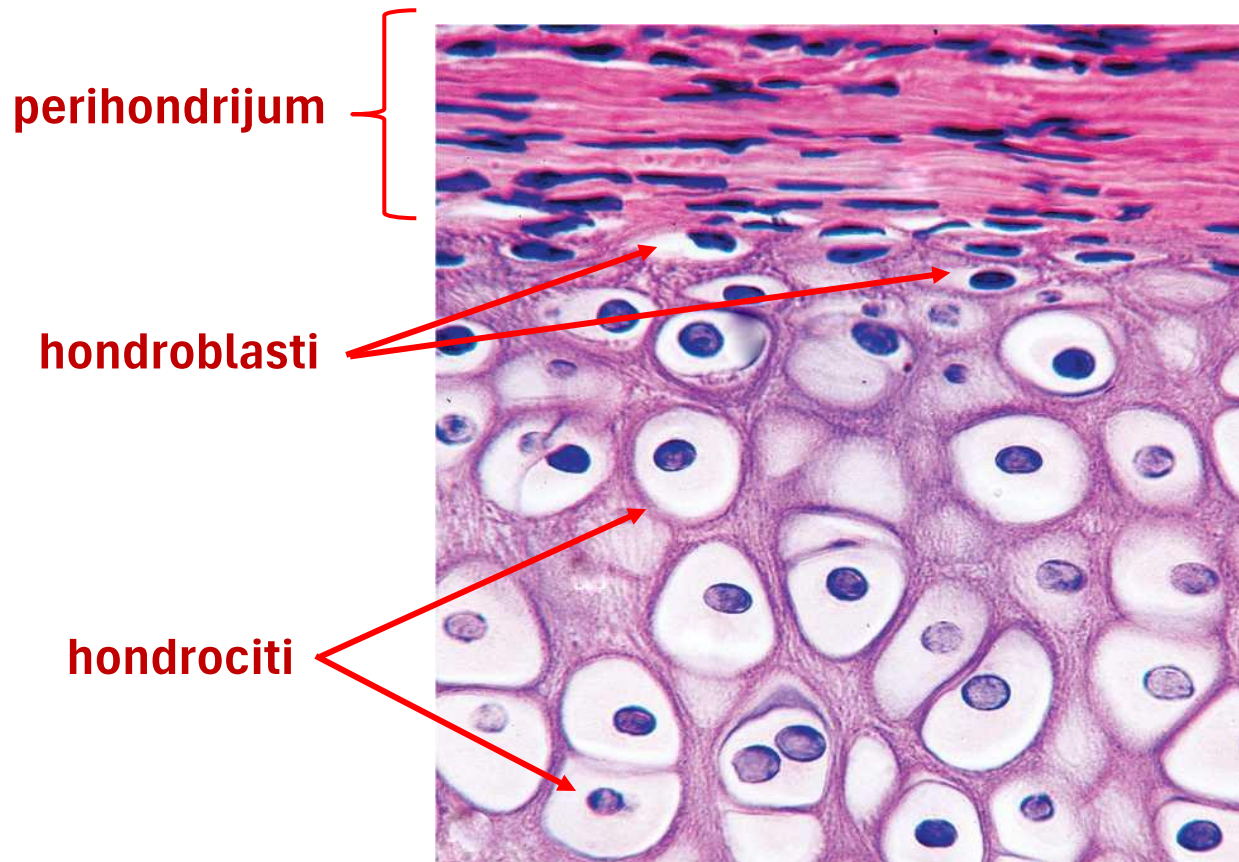
Gdje se nalazi?



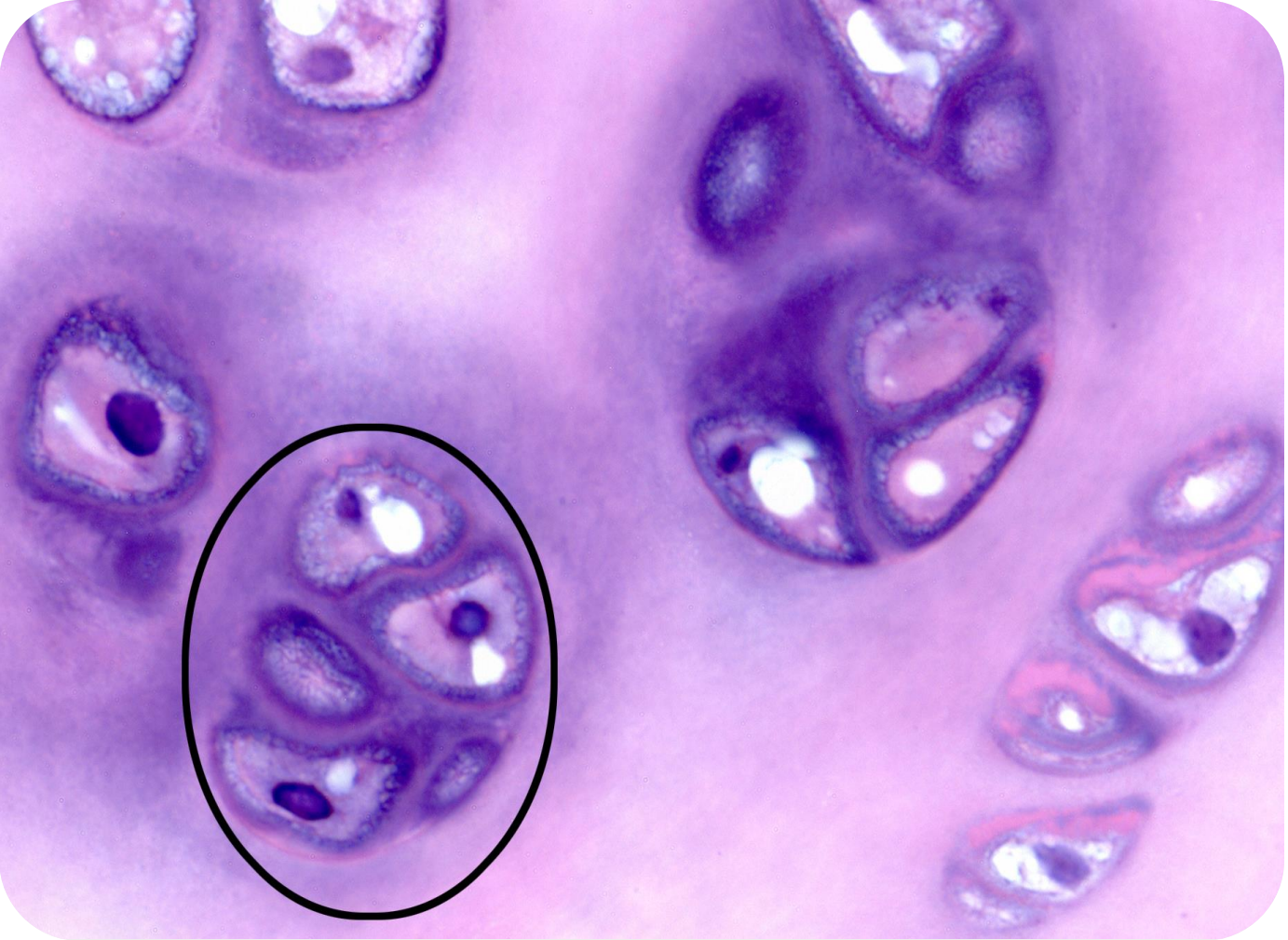
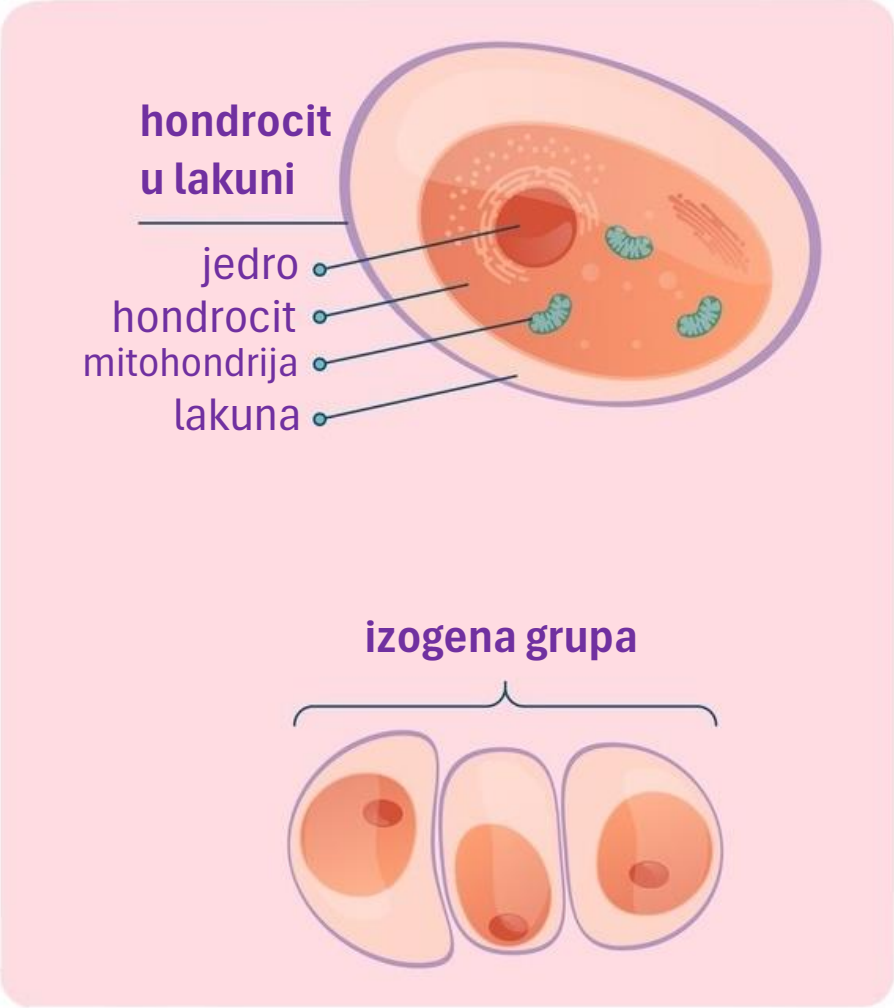
Perihondrijum



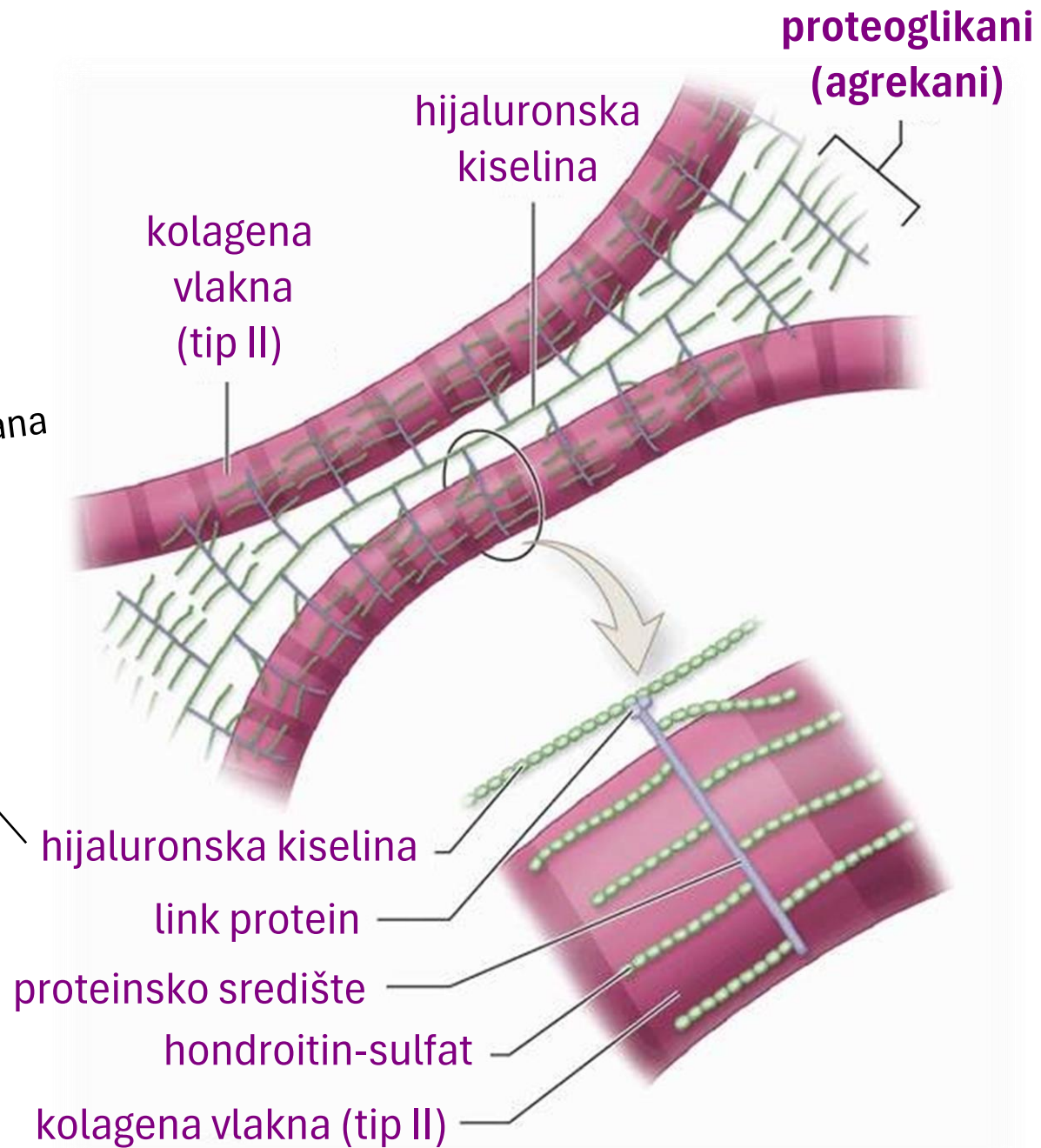
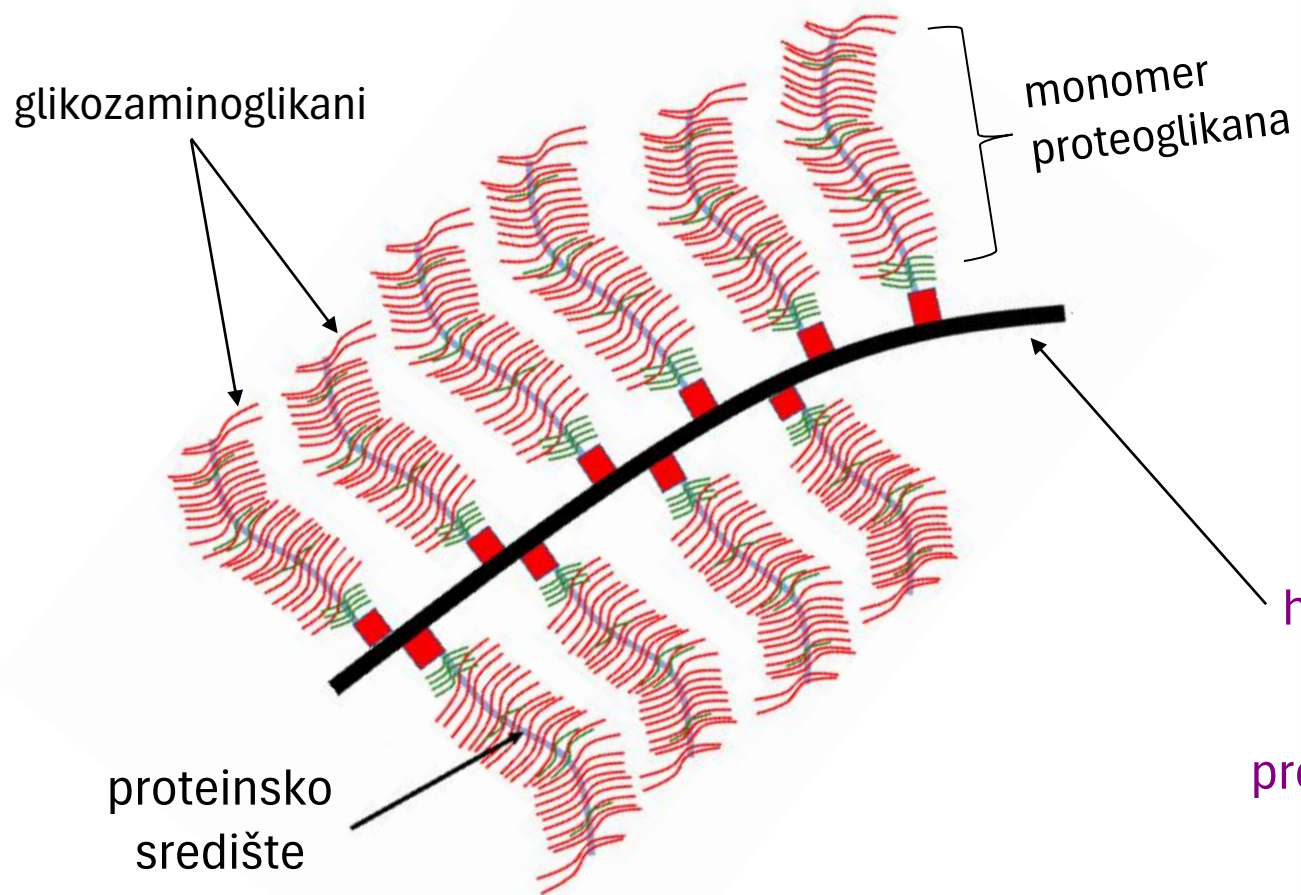
Ćelije hijaline hrskavice



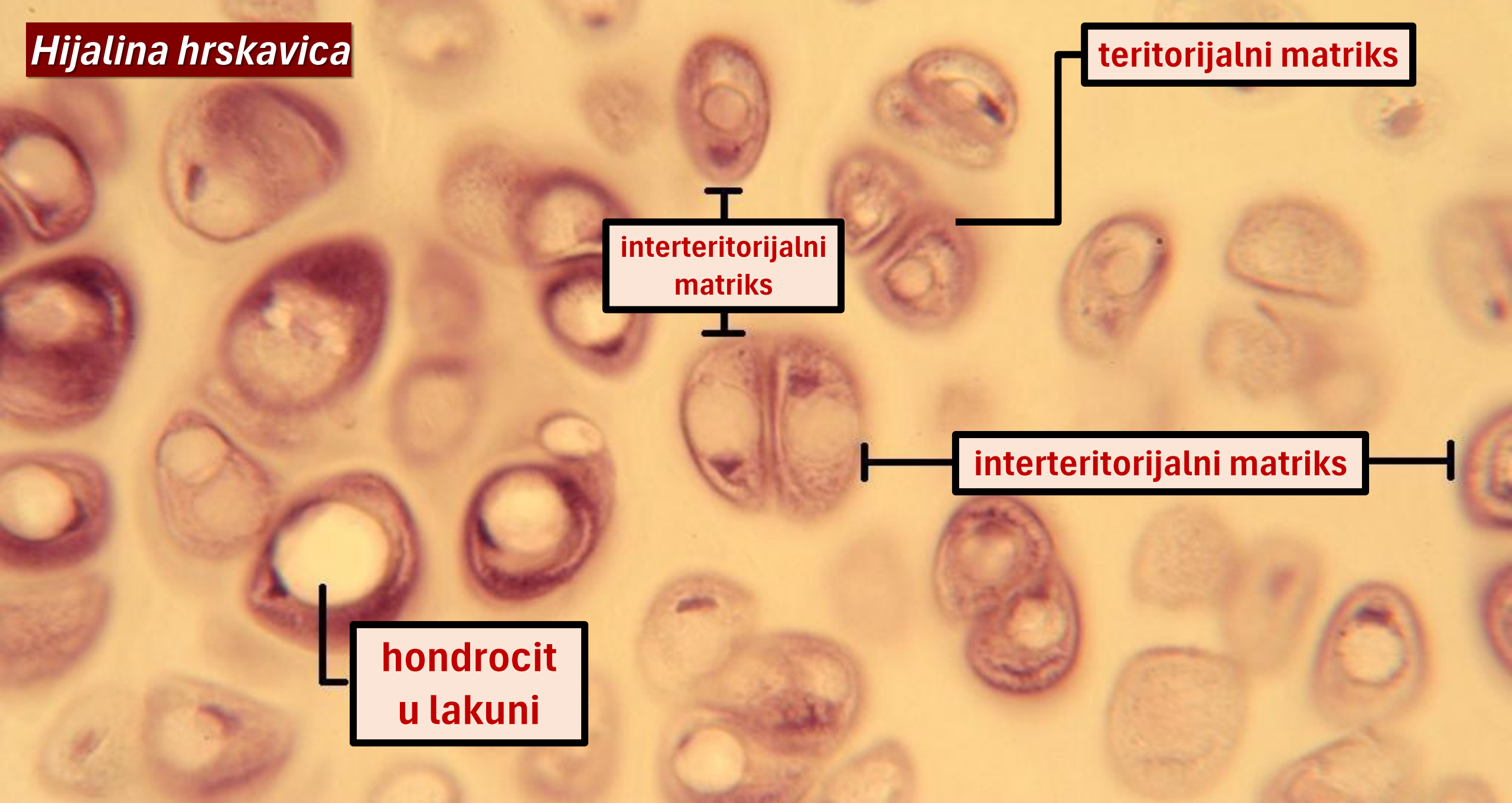
Hondrociti



Ekstracelularni matriks



Hijalina hrskavica



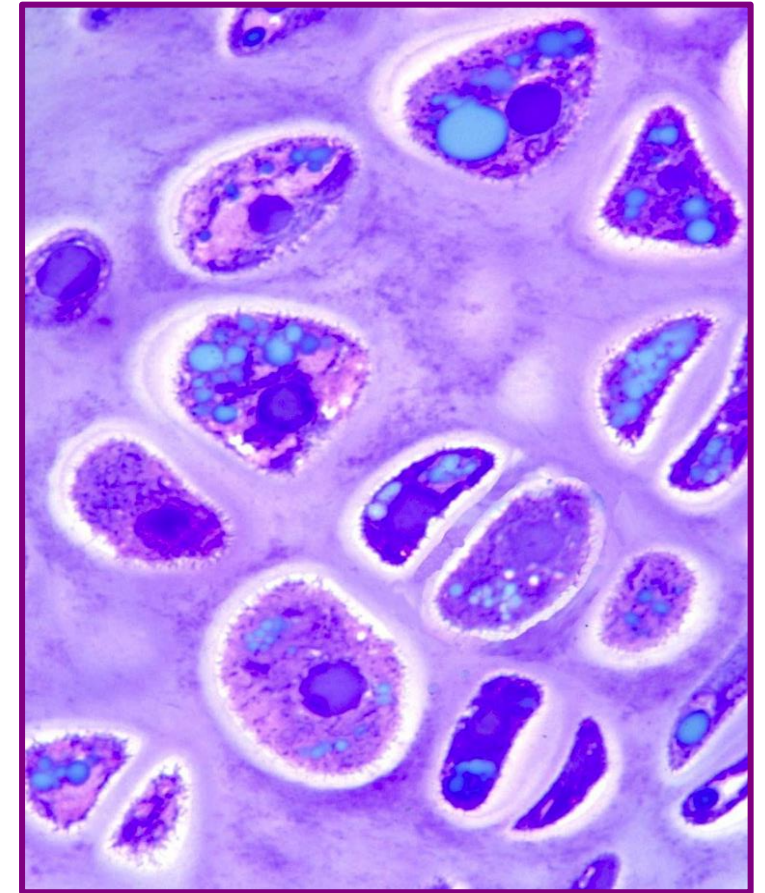
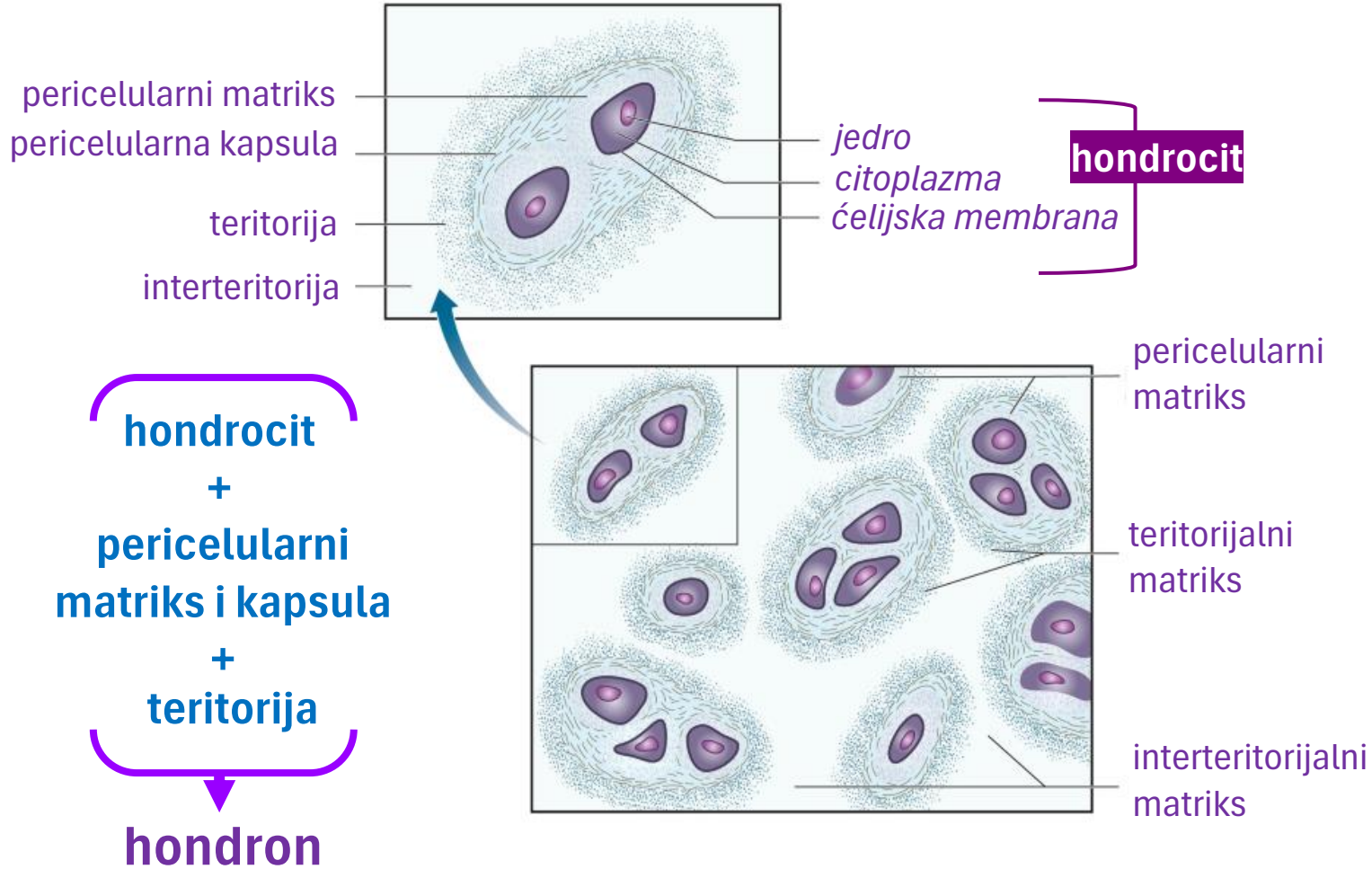
teritorijalni matriks

interteritorijalni matriks

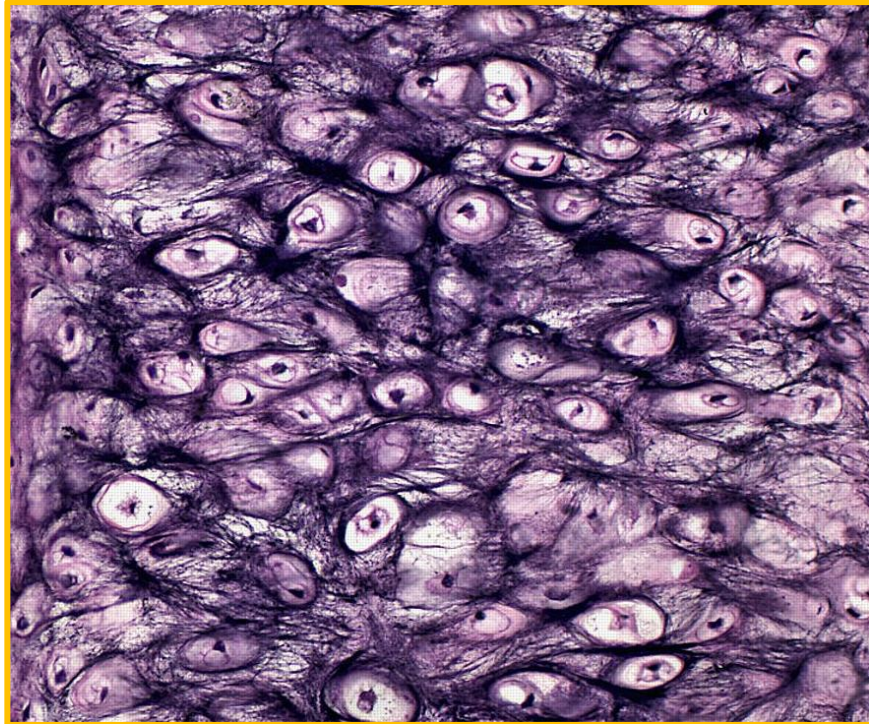
interteritorijalni matriks

hondrocit u lakuni

Hondroцитna mikrosredina



Cartilago elastica



najmanje
zastupljena

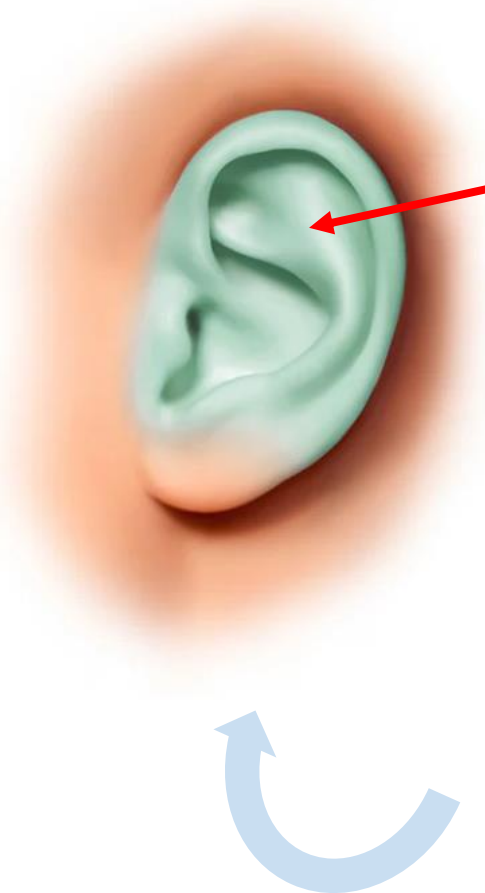žućkaste je boje

boja potiče od **elastičnih vlakana**; opalescentna je

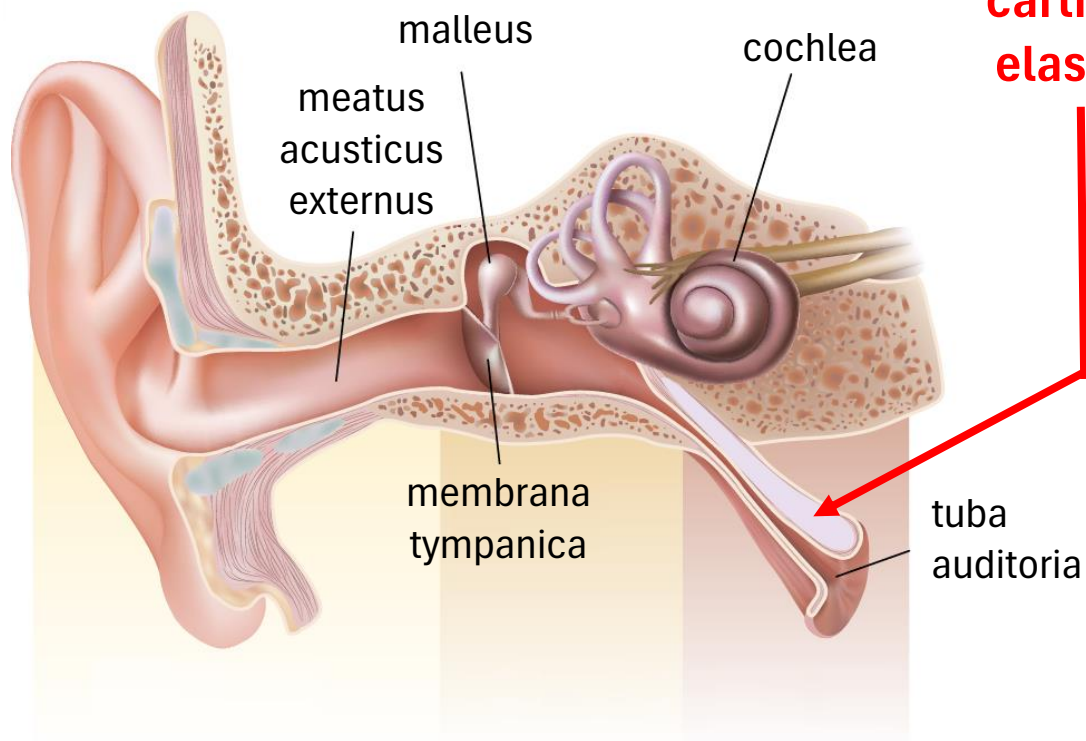
ne okoštava

elastin povećava rezistentnost prema regenerativnim promjenama

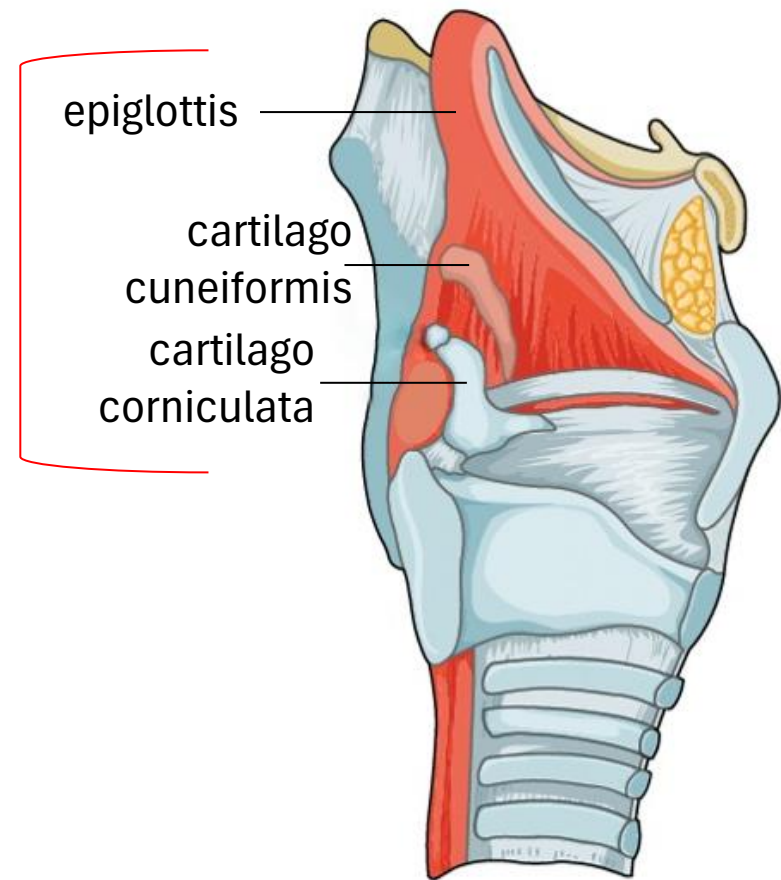
Gdje se nalazi?



cartilago elastica



cartilago elastica



epiglottis

cartilago cuneiformis

cartilago corniculata

Elastična hrskavica

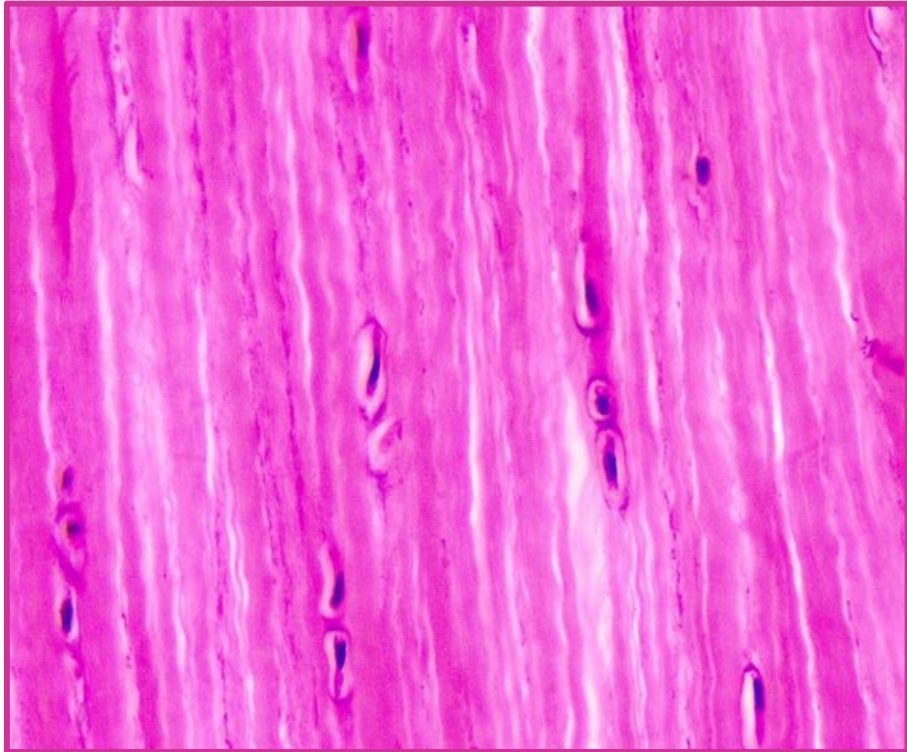
elastična vlakna

interteritorijalni matriks

izogena grupa

hondrocit u lakuni

Cartilago fibrosa



nema
perihondrijum

predstavlja **intermedijerni** oblik tkiva između gustog vezivnog i hijaline hrskavice

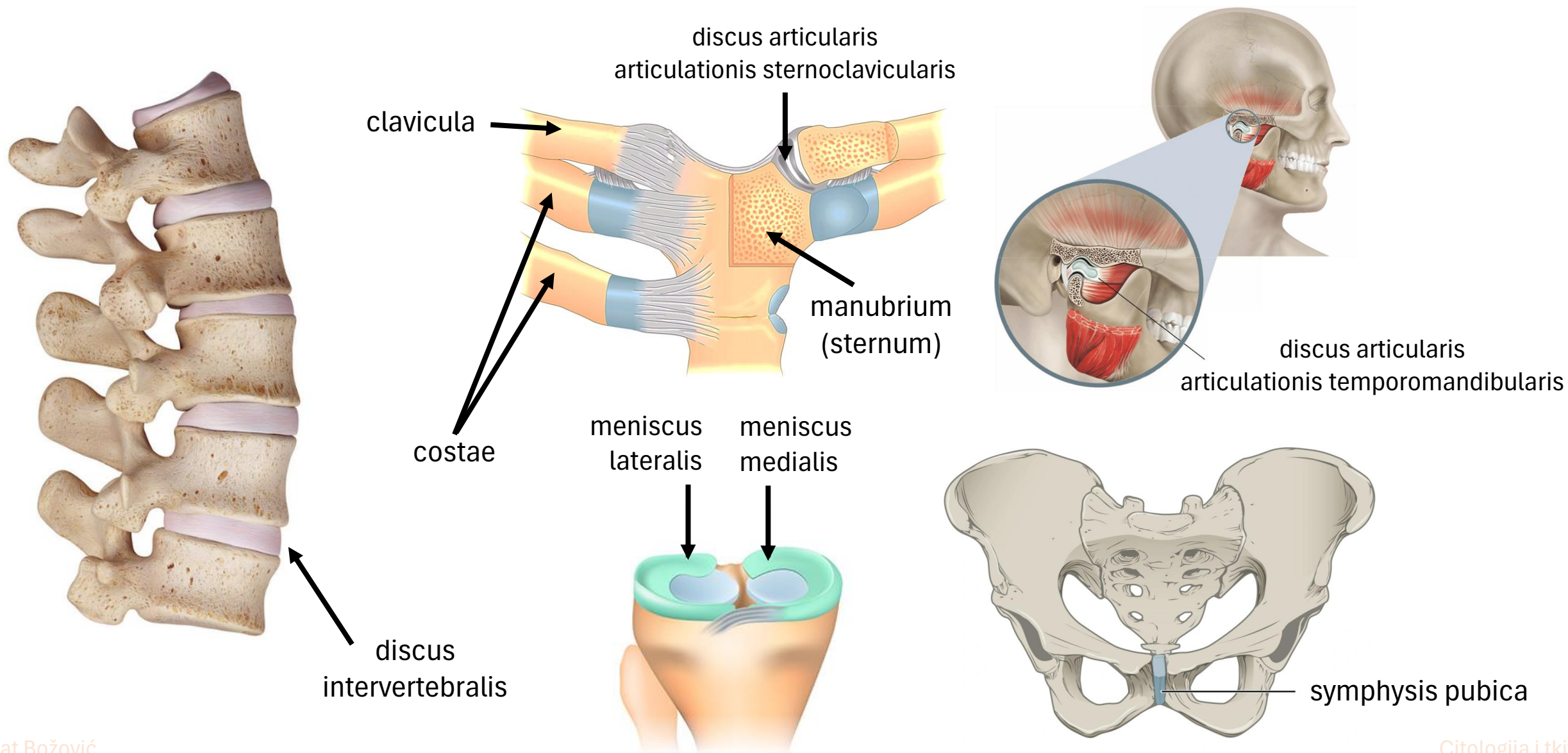
bijele boje od
kolagenih vlakana

kolagena vlakna tip I su organizovana u široke, paralelne snopove

hondrociti
u nizu

rijetko **pojedinačni**, najčešće u uzdužno orjentisanim nizovima

Gdje se nalazi?



Fibrozna hrskavica

kolagena vlakna



teritorijalni matriks




hondrocit u lakuni




hondrociti u nizu



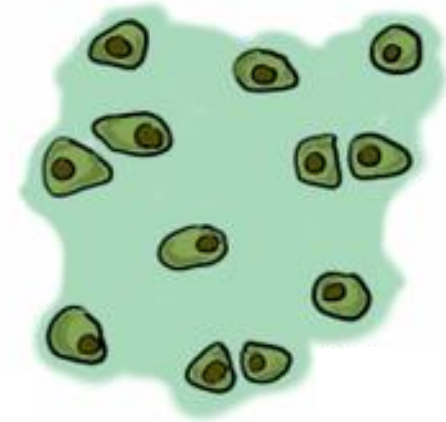Hondrogeneza



hondrogeni blastem
(nastaje zgrušnjavanjem
mezenhimskih ćelija)

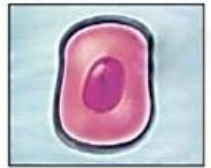

hondroblasti

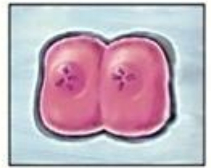

hondroblasti
koji proizvode matriks i postaju
hondrociti

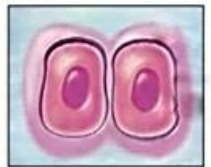Rast hrskavice



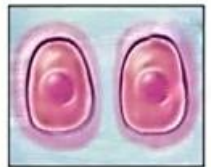hondrocit u lakuni



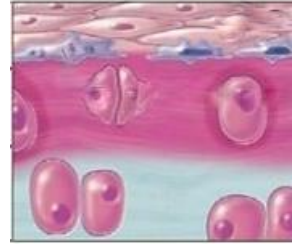
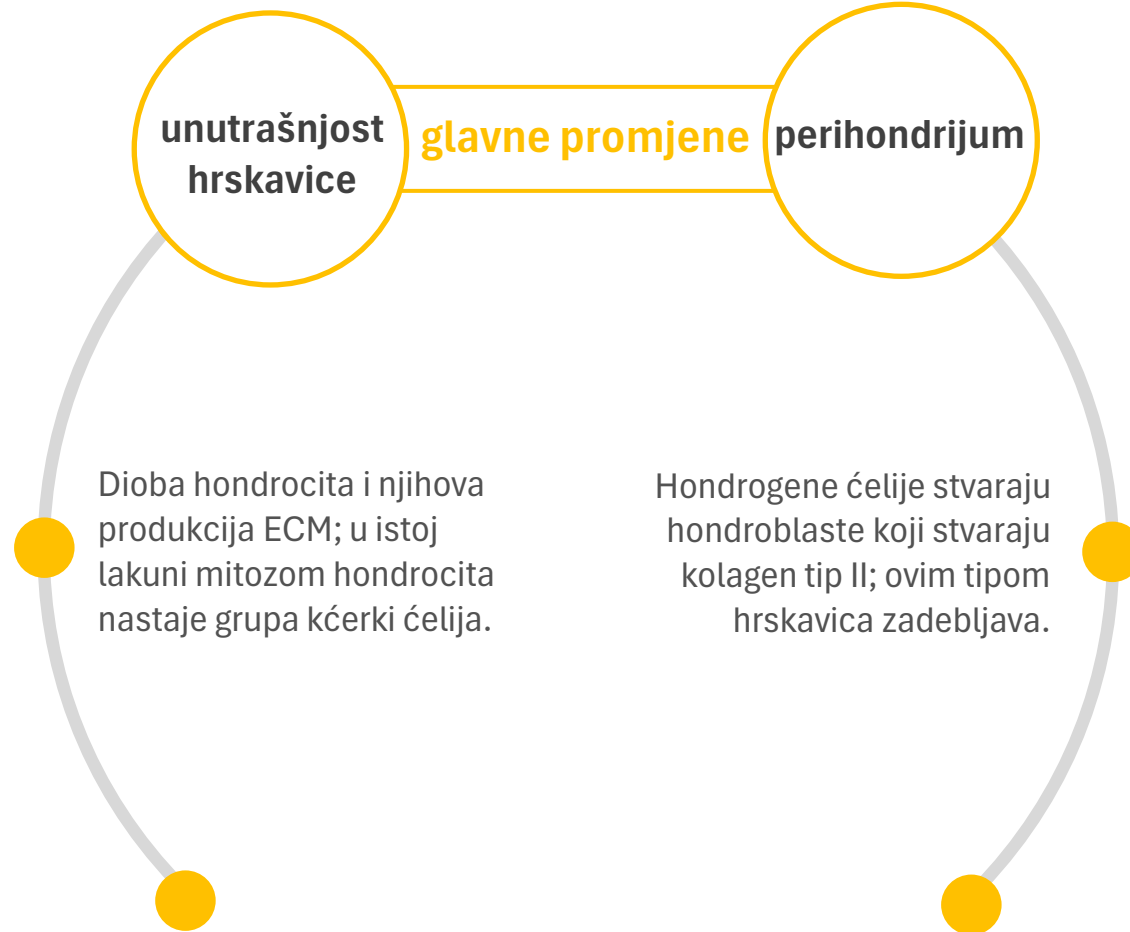dioba hondrocita



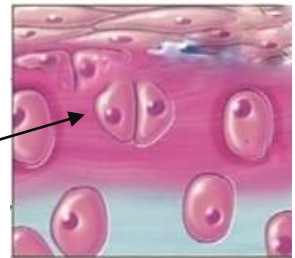
formiranje novog matriksa



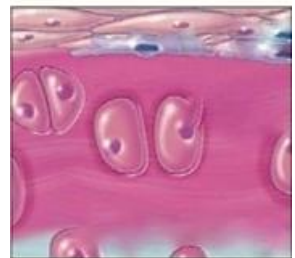
odvajanje hondrocita



novi matriks
stari matriks



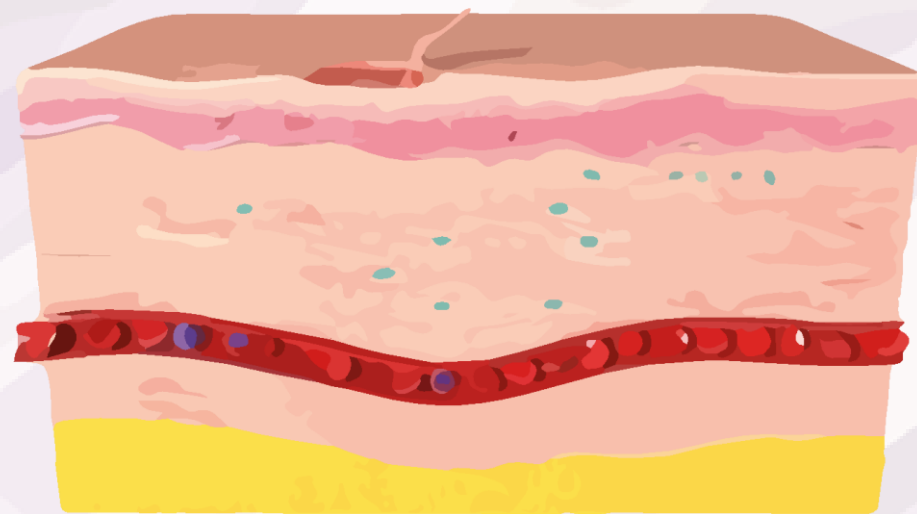
hondroblasti koji stvaraju novi matriks



novi matriks

Citologija i tkiva

Mijat BOŽOVIĆ



PITANJA?

